


Douglas G. Adler MD, FACP, AGAF, FASGE, Series Editor

Direct Percutaneous Endoscopic Jejunostomy: Who, When, How, and What to Avoid



Christopher John Murphy



John C. Fang

INTRODUCTION

Direct percutaneous endoscopic jejunostomy (DPEJ) was first described by Shike in 1987 as a method establishing long term enteral feeding in cancer patients with previous gastric resection.¹ DPEJ is an endoscopic procedure that places a percutaneous feeding tube directly into the jejunum similar to a percutaneous endoscopic gastrostomy (PEG) that places a feeding tube directly into the stomach. There are several approaches to long-term jejunal access, each with unique advantages and disadvantages (Table 1). Percutaneous endoscopic gastrostomy with jejunal extension (PEGJ) remains the most common endoscopic approach due to high reported initial success rates, but tube malfunction is common and requires frequent re-interventions. Percutaneous gastrojejunal feeding tubes are increasingly being placed fluoroscopically, which while not requiring sedation, does involve radiation exposure and may have similarly high tube malfunction rates. Direct percutaneous jejunostomy can also be performed through interventional radiology (IR-J), though there are only limited reports in the literature and it is not widely available.² There are several surgical

jejunostomy (SJ) methods including laparoscopic and needle-catheter techniques, which have success rates approaching 100%. However they require multiple skin incisions, general anesthesia, and if attempted laparoscopically may need conversion to open surgery.³ While DPEJ is not yet widely practiced, advantages include longer durability compared to PEGJ and less invasiveness than surgical methods with similar rates of complications. DPEJ placement does not require special equipment and is similar in technique to the widely practiced PEG, and thus should be more widely available. This article will review the current state of DPEJ, specifically addressing when and in whom it should be considered, the technical approaches to placement, and complications to avoid.

WHO

General Indications for Jejunal Feeding

General indications for jejunal feeding are the need to bypass the stomach due to gastric dysfunction or previous resection. Previous gastric resection can render the stomach dysfunctional both from impaired emptying and increased propensity to reflux. In addition, gastric resection may make the stomach difficult to access percutaneously. More specific indications for

(continued on page 26)

Christopher John Murphy, MD John C. Fang, MD
Division of Gastroenterology and Hepatology,
Department of Internal Medicine, University
of Utah School of Medicine. Salt Lake City, UT

(continued from page 24)

direct jejunal feeding include: gastric obstruction, gastroparesis, high risk of aspiration, previously failed gastric feedings, post-surgical or other anatomy that precludes gastric access, or need for jejunal decompression/venting. Gastrostomy is generally avoided in patients with anticipated esophagectomy due to concern that PEG may compromise the integrity of a future gastric conduit.^{4,5}

DPEJ Indications

Indications for DPEJ are summarized in Table 2. Maple et al.⁶ reported the largest series of 307 patients undergoing DPEJ. In this report 28% of DPEJ were placed due to GI cancer, 21% for gastroparesis, 19% due to previous gastric surgery including partial or total gastrectomy and 13% due to high clinical risk of aspiration. The outcomes of DPEJ placement for specific clinical indications are summarized below.

Aspiration

Patients with recurrent aspiration pose a difficult challenge for clinicians and suffer high morbidity and mortality.⁷ Percutaneous gastrostomy has not been shown to decrease aspiration and aspiration pneumonia. In patients with a history of aspiration, recurrent aspiration after gastrostomy placement has been reported in 11-62% of patients.⁸ Outcomes after PEGJ placement have also been disappointing with multiple studies unable to demonstrate decreased aspiration.^{9,10,11,12} The poor results of PEGJ with recurrent aspiration may be explained by several factors: frequent PEGJ tube malfunction with clogging and proximal migration into the duodenum or stomach and possibly increased

duodenal-gastric reflux due to an extension tube crossing the pylorus.

A few studies have reported decreased aspiration with direct jejunal feeding using SJ¹³ and DPEJ.^{14,15} Panagiotakis et al. reported 11 patients who underwent DPEJ for recurrent aspiration.¹⁵ After DPEJ placement monthly aspiration events decreased significantly from 3.39 to 0.42. Another retrospective analysis compared 205 DPEJ and 58 PEGJ patients and reported aspiration in 18.1% of DPEJ vs. 31.0% of PEGJ patients though this difference was not statistically significant once adjusted for bed-bound status.¹⁶ In another report 16/18 patients with aspiration pneumonia who underwent surgical jejunostomy did not have recurrent aspiration.¹³ While the literature is limited, direct percutaneous jejunostomy feeding may reduce aspiration in high-risk patients.

Gastroparesis

Gastroparesis is a common indication for DPEJ placement.⁶ Good outcomes were recently reported in 14 patients undergoing DPEJ due to severe gastroparesis secondary to perioperative vagus nerve injury during lung transplantation.¹⁷ In these patients, DPEJ placement led to prolonged successful enteral feeding in 90% of patients. If PEG is required for gastric venting, a separate gastrostomy tube can be placed during the same procedure. Combined PEG/DPEJ has been shown to have decreased re-intervention rates and improved patient satisfaction compared to PEGJ alone.¹⁸

Chronic Pancreatitis

Up to 5% of patients with chronic pancreatitis will fail conservative treatment and are candidates for

Table 1. Outcomes of Different Methods of Percutaneous Jejunostomy Placement

Procedure	First Attempt Success Rate (%)	Overall Adverse Event Rate (%)	Serious Adverse Event Rate (%)	Re-intervention Rate (%)
PEGJ ^{16,23,24,36,37,38}	88 – 93	35 - 56	0 – 3.0	22-56
IR-J* ^{39,40,41}	85 – 95	7.7 - 11.3	5 – 11	NA
DPEJ ^{6,23,28,30}	68 – 86	22 – 35	2.0 - 6.3	13.5 - 16.7
SJ* ^{13,42,43 44}	~100	13 – 25	0.6 – 4.0	1.0 – 8.0

* Interventional Radiology placed Jejunostomy (IR-J), Surgical jejunostomy (SJ)

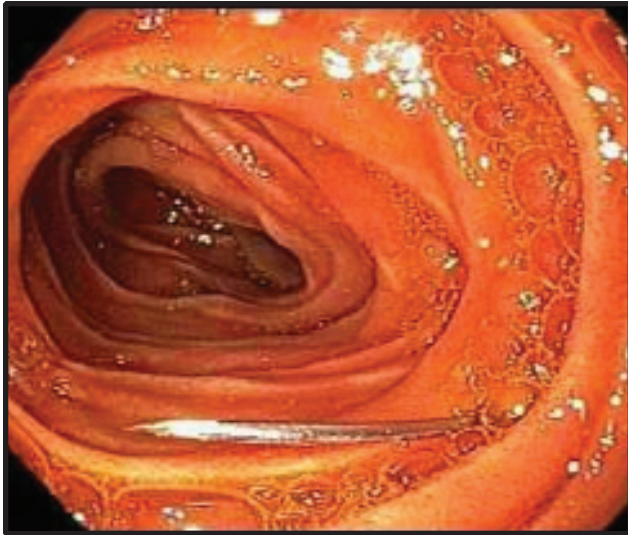


Image 1. Sounding Needle in DPEJ Placement

Sounding needle, entering the jejunum, will subsequently be snared and held under traction to prevent the small bowel from migrating away from abdominal wall during peristalsis.

long term enteral feeding. In these patients, jejunal feeding provides nutritional support while minimally stimulating the exocrine pancreas. In one report, long term jejunal feeding in CP obtained by PEGJ or DPEJ decreased the percentage of patients with pain from 96% to 23% while increasing mean weight by 4.5kg over 6 months.¹⁹ A majority of the literature on jejunal feeding in pancreatitis has utilized PEGJ; however DPEJ has been reported successfully in patients with chronic pancreatitis as well.^{20,21} While more studies are clearly needed, this preliminary data suggests that DPEJ may be an effective means for providing nutritional support in these patients.

Critically Ill Patients

Percutaneous feeding tubes are not often required in the critical care setting due to shorter length of stay, however indications for percutaneous jejunal feeding are similar to those in non-critically ill patients. Successful DPEJ use has been reported in 17 mechanically ventilated ICU patients requiring long-term jejunal feeding for previous aspiration pneumonia (9), failing gastric feeds (4), post-operative anastomotic leak (3) and duodenal obstruction (1).²² All had successful DPEJ placement with one complication of colonic perforation. The remaining 16 tolerated jejunal feedings at goal rates with no episodes of aspiration and 13 were ultimately discharged from the hospital with continued jejunal feedings.

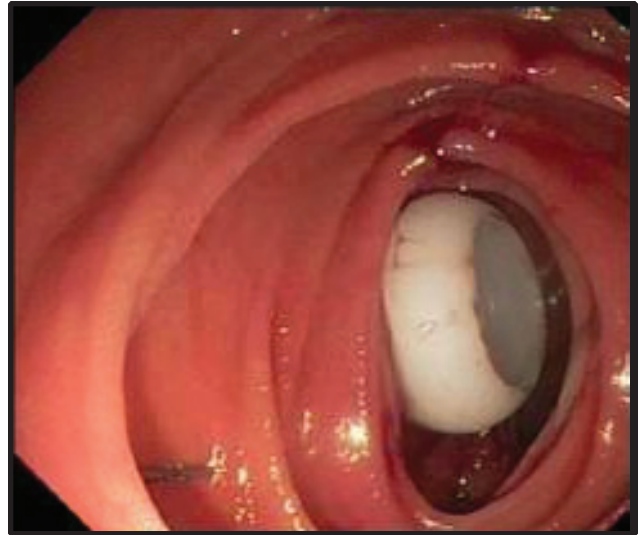

Image 2. DPEJ internal Bolster

The bumper of the DPEJ immediately post placement is shown seated against the wall of the jejunum.

Comparison of PEGJ vs. DPEJ

When considering long-term jejunal access, the endoscopist must choose between PEGJ and DPEJ approaches. PEGJ has higher reported success rates,^{16,23} is generally considered less technically challenging, and is more widely taught in fellowship programs. However, with its longer and smaller caliber tube, PEGJs are prone to frequent clogging and tube migration. Fortunato et al. reported of 102 PEGJs in children, the mean number of jejunal tube replacements was 2.2 tubes per patient (range 1-14) with median tube functional duration of 39 days (range 2-274).²⁴ Tube failure was most commonly due to displacement (31%), clogged tube (22%), and mechanical failure (19%). Similarly high PEGJ malfunction rates were reported in a study following 75 adults with PEGJ placement over 9 months, 53% of patients had tube dysfunction and 41% of patients requiring tube removal or exchange.²⁵

A limited number of studies have directly compared PEGJ and DPEJ with results supporting longer durability and fewer malfunctions with DPEJ. Zopf et al. performed a retrospective analysis of 205 DPEJ and 58 PEGJ procedures and found that DPEJ functioned longer (272 days \pm 414 vs. 130 days \pm 223, $p = 0.023$) with less clogging (9.9% vs. 40%, $p = 0.002$) and tube migration (5.4% vs. 33.3%; $p = 0.005$).¹⁶ Fan et al. found that over 6 months follow-up, DPEJ was associated with significantly longer feeding tube patency and less re-intervention (13.5% DPEJ vs. 55.9% PEGJ, $p = 0.002$).²³

Table 2. Indications and Contraindications for DPEJ

Indications	Absolute Contraindications	Relative Contraindications
Gastroparesis	Coagulopathy	Obesity
High risk for recurrent aspiration	Uncorrected large-volume ascites	Peritoneal Dialysis
Gastric outlet or proximal small bowel obstruction	Severe cachexia	Eating disorders
Previous gastric resection	Small bowel obstruction with inability to pass endoscope distally	Functional nausea or vomiting
Esophageal or gastric malignancy	Intra-abdominal perforation	Small bowel motility disorder
Previously failed PEGJ	Inability to obtain informed consent	Chronic abdominal pain syndrome
Acute and chronic pancreatitis		

These results are consistent with a retrospective study reported in abstract only demonstrating longer durability of combined PEG plus DPEJ compared to PEGJ alone.¹⁸ Finally a randomized prospective trial also reported only in abstract form reported fewer re-interventions and higher patient satisfaction with DPEJ over PEGJ.²⁰

DPEJ Contraindications

Contraindications to DPEJ (Table 2) are similar to PEG and include uncorrected coagulopathy (with standard threshold INR < 1.5 and platelets > 50,000), proximal GI obstruction that would prevent passage of the endoscope to the jejunum, and inability to oppose the small bowel to the anterior abdominal wall. Management of antithrombotics should follow published guidelines. PEG is considered a high-risk procedure for bleeding by the ASGE (American Society of Gastrointestinal Endoscopy) guidelines and similarly so should DPEJ placement.²⁶ Relative contraindications include severe obesity, peritoneal dialysis, ascites and neoplastic, inflammatory, or infiltrative diseases of the small bowel and/or anterior abdominal wall. In addition, other standard general contraindications to endoscopy apply as well.

WHEN

As recommended by ASGE Practice Guidelines²⁷ nasoenteric feeding is the preferred approach for

patients expected to be able to resume oral feeding within 30 days. Therefore DPEJ should be considered in the management of patients with an indication for jejunal access expected to require enteral feeding for greater than 30 days.

If it is highly likely that jejunal feeding will be needed for > 30 days, it is not necessary to wait until then to place DPEJ. Alternatively, DPEJ placement is never urgently indicated and thus naso and oro-enteric feeding tubes can be used until clinical parameters are maximized for safe percutaneous placement or to determine if clinical improvement will eliminate the need for longer term jejunal feeding.

HOW

Pre-procedural Preparation

As an extension of ASGE guidelines for PEG, pre-procedure laboratory evaluation is generally not required for DPEJ placement. Prophylactic antibiotics, typically cefazolin 1gm IV, are indicated unless the patient is already receiving other adequate antibiotic coverage. Anti-spasmodics such as glucagon and hyoscine can be used during the procedure to help reduce jejunal peristalsis. The procedure is performed with the patient in the supine position. DPEJ may be performed under conscious sedation, monitored anesthesia care, or general

(continued on page 30)

(continued from page 28)

anesthesia. Procedure times are greater compared to PEG and therefore at our institution we now perform all initial DPEJ placements under general anesthesia to decrease aspiration risk during a prolonged procedure in the supine position. Use of CO₂ for insufflation is also useful to reduce postoperative discomfort and risk of bowel over insufflation. Standard commercially available PEG kits can be used for the procedure with the only caveat that the looped guide wire and snare are long enough to pass through whatever enteroscope is used for the procedure. The authors most commonly use a pediatric colonoscope for DPEJ placement, but

use of dedicated balloon and non-balloon enteroscopes have been reported as well.

Technique (see Figure 1)

DPEJ is technically similar to a pull PEG procedure with the main difference that additional procedural time is required to reach the small bowel and identify an appropriate area for direct jejunal puncture. The enteroscope is advanced into the jejunum and an appropriate puncture site is identified by observing transillumination of light in a discrete area on the anterior abdominal wall. To further confirm the site, external pressure using a single finger should produce

Table 3. Summary of DPEJ Placement Success Rates and Complications from Largest Reported Series

Author	Success	Follow-up	Severe AE	Mild and Moderate AE	Re-Intervention	Death
Maple et al. ⁶ (2005)	209/307 (68%)	251 days	N=14 (4.5%) Serious Bleeding ψ (3) Bowel Perforation (7) Jejunal Volvulus (3) Aspiration (1)	N=67 (22%) Infection (25) Pain (19) Chronic Fistula (9) Aspiration Pneumonia (1) Jejunal Hematoma (1)	N=35 (16.7%)	N=1 (0.3%)
Shike et al. ²⁸ (1996)	129/150 (86%)	113 days	N=3 (2.0%) Bowel perforation (1) Bleeding (1) Abscess (1)	N=34 (28%) Tube leakage (12) Infection (9) Tube malfunction (3) Aspiration (3)	Not reported	None
Mackenzie et al. ³⁰ (2008)	65/80 (81%)	120 days	N=5 (6.3%) Necrotizing Fasciitis (1) Jejunal obstruction (1) Jejunal volvulus (2) Sepsis (1)	N=28 (35%) Pain* (14) Infection (12)	Not reported	N=1 (1.3%)
Fan et al. ²³ (2002)	56/77 (72.7%)	180 days	Not fully reported: Jejunal volvulus (1)	Not fully reported: Tube leakage (1) Infection (1) Pain (1) Site ulceration (1)	N = 5 (13.5%)	None

* This study included post-operative pain as a mild complication

ψ Denotes a complication responsible for mortality

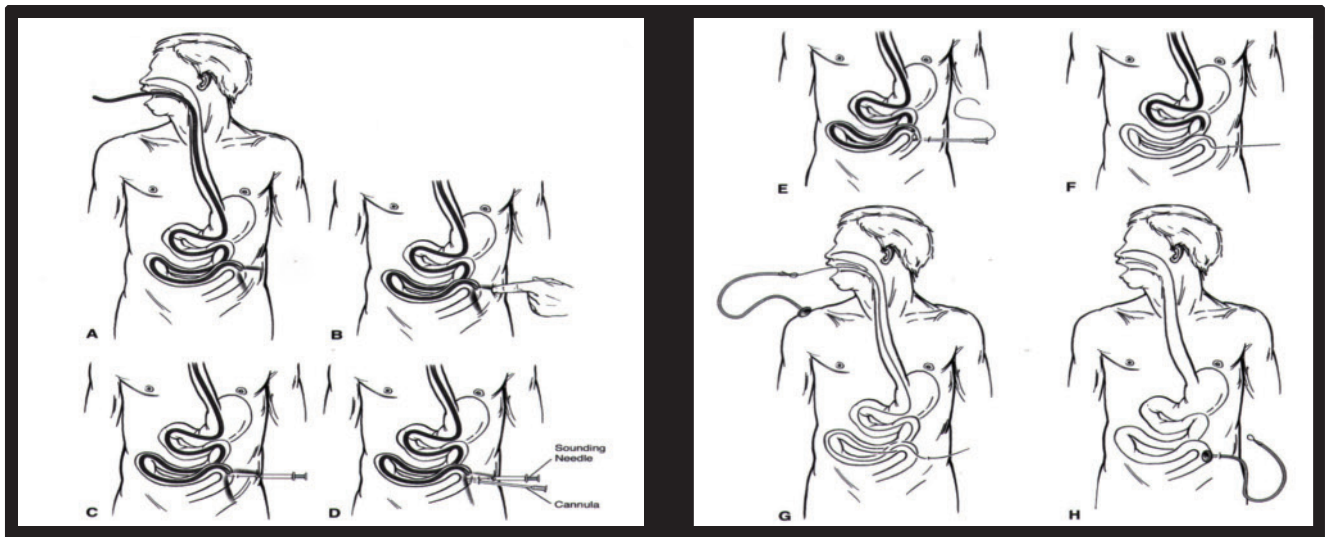


Figure 1. DPEJ Placement

(A) The enteroscope is advanced and transillumination of a discrete area of the anterior abdomen is achieved. (B) A discrete jejunal wall indentation should be reproducible with direct single-finger compression at the site of transillumination. (C) Sounding needle is inserted via the “safe-track” technique and ensnared. (D) The needle/cannula is inserted along the same path as the sounding needle and ensnared. (E) Guide wire is fed through the cannula and grasped. (F) The endoscope is retracted, pulling the guide-wire out of the patient’s mouth. (G) The jejunal tube is attached to the insertion wire. (H) The assembly is pulled until the feeding tube is snug against the wall of the jejunum. *Obtained from Techniques in Gastrointestinal Endoscopy Vol 3, Ginsberg GG. Direct Percutaneous Endoscopic Jejunostomy, 42-49*

a discrete indentation in the jejunal wall visualized by the endoscope. Both excellent transillumination and discrete finger indentation are required for safe jejunal puncture. After sterile skin preparation and local anesthesia, a sounding needle (typically 21 gauge 1.5-inch needle) is advanced into the jejunal lumen using the “safe-track” technique (see Table 4). Once visualized in the jejunum (Image 1), the tip of the sounding needle is immediately secured with a snare to prevent migration of the jejunum away from the abdominal wall. Using a scalpel, a stab incision is made immediately adjacent to the sounding needle and the larger trochar/needle cannula (~14 gauge) is inserted into the jejunum parallel to the sounding needle again using safe track technique and the snare is transferred from sounding needle to the trocar. From this point the procedure follows the same steps as a standard pull PEG technique. The looped guidewire is fed through the trochar, snared and withdrawn with the endoscope through the mouth. The jejunostomy tube is attached to the wire and pulled into place until the bumper is seated in the jejunum (Image 2). Endoscopic re-visualization can be performed at the operator’s discretion to confirm placement, but is not necessary in uncomplicated procedures.

Leaving the jejunal port open immediately after successful placement facilitates small bowel decompression. Tube feeding can be initiated immediately at 25-50mL/hour and titrated to goal rate as tolerated. Feeding with standard polymeric formulas can be used in almost all patients unless there is concern for malabsorption or pancreatitis. There is little information regarding the time for secure adherence of the jejunum to the abdominal wall, thus it is advisable to wait at least 4 weeks prior to removal of a DPEJ. It is likely that mature stoma tract formation occurs much earlier unless the patient has poor wound healing from steroids, diabetes mellitus, immunosuppression, or severe malnutrition.

Success Rates

In the larger studies DPEJ success rates have ranged from 65-86% (Table 3).^{6,16,28,30} Increased success is consistently reported in patients with prior gastric or esophageal resection. This is likely secondary to post-operative anatomy being conducive to passing the endoscope further into the small bowel and adhesions fixing the jejunum to the anterior abdominal wall facilitating site identification. In the largest series of DPEJ placement the most common reasons for failure

Table 4. “Safe Track” Needle Technique

1. Identify jejunal access site with successful transillumination and finger indentation.
2. Advance sounding needle under constant negative pressure by pulling back on the plunger of the syringe until air is aspirated.
3. If air is aspirated without endoscopic visualization of the needle tip, an intervening viscus has been entered and the attempt should immediately be discontinued.
4. If air is aspirated with simultaneous needle tip visualization, a direct safe path to the jejunum has been established.

Table 5. Tips for Successful DPEJ Placement

1. Antispasmodics to help reduce jejunal peristalsis.
2. Use of the transillumination function on the light processor with ambient room lights and unnecessary monitors off maximizes chance for identifying an appropriate location.
3. Insertion near abdominal scars does not need to be avoided, as these sites may represent site of intestinal adhesion that may facilitate appropriate site for jejunostomy.
4. Maintain constant anchoring of the jejunum to the abdominal wall by snaring the sounding needle and trochar.

were absent transillumination/finger indentation (20%), suboptimal transillumination/finger-indentation (5.5%), inability to reach the jejunum (2.6%), inability to pass the scope concomitant with failure to transilluminate (1.9%), and sedation complication (1.3%).⁶

As with other endoscopic procedures, DPEJ placement success appears to follow a learning curve. One study reported success rates of inexperienced operators (<66 procedures) was 63.7% compared to 77.5% and 74.5% in medium (67-187 procedures) and highly experienced endoscopists (>188 procedures) respectively.¹⁶ Obesity has also been shown to decrease successful DPEJ placement in two studies. The first reported patients with abdominal wall thickness on CT scan <3cm (vs. ≥3cm) had successful placement 73% vs. 39% (p= 0.003) of the time with no successful placements when thickness exceeded 4 cm.²⁹ In the second study, increasing BMI was directly associated with decreased success rates with BMI < 18.5 (96% success), BMI 18.5-24.9 (81% success), BMI 25-29.9 (73% success) and BMI > 30 (60% success).³⁰

If DPEJ is initially unsuccessful, PEGJ can be placed during the same procedure, although there is data that repeat DPEJ attempt under general anesthesia with a dedicated balloon enteroscope is often successful.³¹ A number of helpful hints have been described to aid in successful DPEJ placement (Table 5).

Adjunctive Techniques

Several adjunctive methods to the standard DPEJ technique described above have been reported. Adding fluoroscopy to the procedure allows confirmation that the endoscope has passed the ligament of Treitz and can be a useful tool to visually guide the sounding needle to the snare.³² A success rate of 97.5% was reported in a series of 40 patients utilizing the selective use of a 15 cm long drainage needle with intermittent fluoroscopic guidance.³³ The authors felt that using a longer needle facilitated deeper penetration in obese patients in whom traditional transillumination or jejunal indentation may not be feasible. The use of ultrasound during DPEJ has also been described to help delineate a targeted loop of jejunum, confirm close proximity to the anterior abdominal wall, and rule out intervening viscus when transillumination has failed.³⁴ Routine use of fluoroscopy and ultrasound have not been widely adopted, but they remain useful modalities to consider in potentially difficult patients.

(continued on page 34)

(continued from page 32)

Perhaps the most promising adjuvant technique for DPEJ placement has been the use of single³⁵ and double-balloon enteroscopy (DBE). Song et al. reported a series of 10 patients who failed standard DPEJ with pediatric colonoscopes and subsequently underwent repeat DPEJ with DBE with 100% success.³¹ The reasons for initial failures were inability to transilluminate (5 patients), altered anatomy of efferent limb (3 patients), and limited endoscopic advancement due to looping and small-bowel angulation (1 patient each). The authors further reported 93% success (27/29 patients) utilizing DBE for initial DPEJ placements. In this series repeat DPEJ with DBE was performed under general anesthesia in almost all patients. The authors hypothesized that improved outcomes with DBE were due to the ability to pass further into the small bowel from reduced instrument looping and a more flexible tip on the DBE scope allowing passage through small bowel angulation and narrowing.

WHAT TO AVOID

Inappropriate Indications

DPEJ placement should be considered only with extreme caution for patients with small bowel motility disorders or for patients with eating disorders such as anorexia or bulimia, functional nausea or vomiting, or patients with chronic pain (Table 2). If there is concern that small bowel feeding would not be tolerated, a trial of nasojejunal feeding prior to more invasive DPEJ placement is warranted.

Complication Rates

Reported complications from the larger DPEJ studies are summarized in Table 3. Complications are generally rare, but severe adverse events reported in 2-6.3% of cases. These include jejunal volvulus, necrotizing fasciitis, bowel perforation, and bleeding. Small bowel volvulus is a potential complication of jejunostomy regardless of placement technique as the relatively unfixed small bowel can rotate around the single point fixation of the jejunostomy. Small bowel volvulus is likely less common in patients with previous abdominal surgery due to adhesions that may fix the small bowel at multiple locations. Use of T-fasteners to establish additional points of jejunal fixation near the site of the DPEJ may reduce the risk of jejunal volvulus. As noted previously obesity decreases success rates and it has

also been associated with a trend towards more adverse events. In one series the adverse event rate was 19% in patients with BMI > 25 and 4 of 5 severe adverse events also occurred in patients with BMI > 25.³⁰

CONCLUSION

DPEJ provides direct jejunal access without the morbidities of surgery. It should be considered whenever long-term jejunal access is required. The most common indications are altered gastric anatomy, gastroparesis, GI malignancies, and recurrent aspiration. Limited data suggests that DPEJ provides more reliable long-term functionality, fewer re-interventions, and decreased risk for aspiration compared to the more commonly practiced PEGJ. DPEJ use has been limited due to perceived need for greater technical expertise, however the procedure is very similar to the pull PEG technique with the distinction that greater time and caution is required while identifying the site for direct jejunal access. Placement success can be improved by using a number of helpful hints and adjuvant techniques including use of balloon enteroscopy. Complication rates are similar to other methods of direct jejunal feeding tubes and include volvulus, necrotizing fasciitis and persistent jejunal fistula. At this time improvements in DPEJ techniques and further prospective studies comparing DPEJ to other methods of jejunal access are needed, but present data suggest that DPEJ should be more frequently practiced. ■

References

1. Shike M, Schroy P, Ritchie MA, Lightdale CJ, Morse R. Percutaneous endoscopic jejunostomy in cancer patients with previous gastric resection. *Gastrointest Endosc.* 1987 Oct;33(5):372-4.
2. Overhagen Hv, Schipper J. Percutaneous jejunostomy. *Semin Intervent Radiol.* 2004 Sep;21(3):199-204.
3. Han-Geurts IJ, Lim A, Stijnen T, Bonjer HJ. Laparoscopic feeding jejunostomy: a systematic review. *Surg Endosc.* 2005 Jul;19(7):951-7.
4. Schrag SP, Sharma R, Jaik NP, Seamon MJ, Lukaszczuk JJ, Martin ND, Hoey BA, Stawicki SP. Complications related to percutaneous endoscopic gastrostomy (PEG) tubes. A comprehensive clinical review. *J Gastrointest Liver Dis.* 2007 Dec;16(4):407-18.
5. Ajani J *et al.*, National Comprehensive Cancer Network. Esophageal and Esophagogastric junction cancers. Clinical practice guidelines in oncology v2. *J Natl Compr Canc Netw.* 2013 June.
6. Maple JT, Petersen BT, Baron TH, Gostout CJ, Wong Kee Song LM, Buttar NS. Direct percutaneous endoscopic jejunostomy: outcomes in 307 consecutive attempts. *Am J Gastroenterol.* 2005 Dec;100(12):2681-8.

(continued on page 36)

(continued from page 34)

7. Marik, PE. Aspiration pneumonitis and aspiration pneumonia. *NEJM*. 2001 Mar; 344(9): 665-671.
8. Finucane TE, Bynum JP. Use of tube feeding to prevent aspiration pneumonia. *Lancet*. 1996 Nov 23;348(9039):1421-4. Review. Erratum in: *Lancet* 1997 Feb 1;349(9048):364.
9. Cogen R, Weinryb J, Pomerantz C, Fenstermacher P. Complications of jejunostomy tube feeding in nursing facility patients. *Am J Gastroenterol*. 1991 Nov;86(11):1610-3.
10. Henderson JM, Strodel WE, Gilinsky NH. Limitations of percutaneous endoscopic jejunostomy. *JPEN J Parenter Enteral Nutr*. 1993 Nov-Dec;17(6):546-50.
11. Kadakia SC, Sullivan HO, Starnes E. Percutaneous endoscopic gastrostomy or jejunostomy and the incidence of aspiration in 79 patients. *Am J Surg*. 1992 Aug;164(2):114-8.
12. Lazarus BA, Murphy JB, Culpepper L. Aspiration associated with long-term gastric versus jejunal feeding: a critical analysis of the literature. *Arch Phys Med Rehabil*. 1990 Jan;71(1):46-53.
13. Weltz CR, Morris JB, Mullen JL. Surgical jejunostomy in aspiration risk patients. *Ann Surg*. 1992 Feb;215(2):140-5.
14. Shike M, Berner YN, Gerdes H, Gerold FP, Bloch A, Sessions R, Strong E. Percutaneous endoscopic gastrostomy and jejunostomy for long-term feeding in patients with cancer of the head and neck. *Otolaryngol Head Neck Surg*. 1989 Nov;101(5):549-54.
15. Panagiotakis PH, DiSario JA, Hilden K, Ogara M, Fang JC. DPEJ tube placement prevents aspiration pneumonia in high-risk patients. *Nutr Clin Pract*. 2008 Apr-May;23(2):172-5.
16. Zopf Y, Rabe C, Bruckmoser T, Maiss J, Hahn EG, Schwab D. Percutaneous endoscopic jejunostomy and jejunal extension tube through percutaneous endoscopic gastrostomy: a retrospective analysis of success, complications and outcome. *Digestion*. 2009;79(2):92-7.
17. Toussaint E, Van Gossum A, Ballarin A, Le Moine O, Estenne M, Knoop C, Devière J, Arvanitakis M. Percutaneous endoscopic jejunostomy in patients with gastroparesis following lung transplantation: feasibility and clinical outcome. *Endoscopy*. 2012 Aug;44(8):772-5.
18. Krivian K, Peterson K, DiSario J, Fang J. Comparison of percutaneous endoscopic gastrostomy with jejunal extension to combined direct percutaneous endoscopic gastrostomy/direct percutaneous endoscopic jejunostomy. *Gastrointest Endosc*. 2003;57:AB159.
19. Stanga Z, Giger U, Marx A, DeLegge MH. Effect of jejunal long-term feeding in chronic pancreatitis. *JPEN J Parenter Enteral Nutr*. 2005 Jan-Feb;29(1):12-20.
20. DeLegge M, Ginsberg G, McClasve S, et al. Randomized prospective comparison of direct percutaneous endoscopic jejunostomy vs percutaneous endoscopic gastrostomy with jejunal extension feeding tube placement for enteral feeding [abstract]. *Gastrointest Endosc* 2004;59:AB158.
21. Nathanson, A., C. Parrish, J. Fang, and P. Yeaton. A retrospective study of enterally fed adult patients with pancreatitis. *Nutr Clin Pract*. 1999; 14: 100.
22. Barrera R, Schattner M, Nygard S, Ahdoot M, Ahdoot A, Adeyeye S, Groeger J, Shike M. Outcome of direct percutaneous endoscopic jejunostomy tube placement for nutritional support in critically ill, mechanically ventilated patients. *J Crit Care*. 2001 Dec;16(4):178-81.
23. Fan AC, Baron TH, Rumalla A, Harewood GC. Comparison of direct percutaneous endoscopic jejunostomy and PEG with jejunal extension. *Gastrointest Endosc*. 2002 Dec;56(6):890-4.
24. Fortunato JE, Darbari A, Mitchell SE, Thompson RE, Cuffari C. The limitations of gastro-jejunal (G-J) feeding tubes in children: a 9-year pediatric hospital database analysis. *Am J Gastroenterol*. 2005 Jan;100(1):186-9.
25. Wolfson HC, Kozarek RA, Ball TJ, Patterson DJ, Botoman VA. Tube dysfunction following percutaneous endoscopic gastrostomy and jejunostomy. *Gastrointest Endosc*. 1990 May-Jun;36(3):261-3.
26. Eisen, Glenn M., et al. "Guideline on the management of anticoagulation and antiplatelet therapy for endoscopic procedures." *Gastrointestinal endoscopy*. 2002; 55(7): 775-779.
27. ASGE Standards of Practice Committee. The role of endoscopy in enteral feeding. *Gastrointest Endosc*. 2011 Jul;74(1):7-12.
28. Shike M, Latkany L, Gerdes H, Bloch AS. Direct percutaneous endoscopic jejunostomies for enteral feeding. *Gastrointest Endosc*. 1996 Nov;44(5):536-40.
29. Maple JT, Petersen BT, Baron TH, Harewood GC, Johnson CD, Schmit GD. Abdominal CT as a predictor of outcome before attempted direct percutaneous endoscopic jejunostomy. *Gastrointest Endosc*. 2006 Mar;63(3):424-30.
30. Mackenzie SH, Haslem D, Hilden K, Thomas KL, Fang JC. Success rate of direct percutaneous endoscopic jejunostomy in patients who are obese. *Gastrointest Endosc*. 2008 Feb;67(2):265-9.
31. Song LM, Baron TH, Saleem A, Bruining DH, Alexander JA, Rajan E. Double-balloon enteroscopy as a rescue technique for failed direct percutaneous endoscopic jejunostomy when using conventional push enteroscopy (with video). *Gastrointest Endosc*. 2012 Sep;76(3):675-9.
32. Shetzline MA, Suhocki PV, Workman MJ. Direct percutaneous endoscopic jejunostomy with small bowel enteroscopy and fluoroscopy. *Gastrointest Endosc*. 2001 May;53(6):633-8.
33. Moran GW, Fisher NC. Direct Percutaneous Endoscopic Jejunostomy: High Completion Rates with Selective Use of a Long Drainage Access Needle. *Diagn Ther Endosc*. 2009;2009:520879.
34. Sharma VK, Close T, Bynoe R, Vasudeva R. Ultrasound-assisted direct percutaneous endoscopic jejunostomy (DPEJ) tube placement. *Surg Endosc*. 2000 Feb;14(2):203-4.
35. Aktas H, Mensink PB, Kuipers EJ, van Buuren H. Single-balloon enteroscopy-assisted direct percutaneous endoscopic jejunostomy. *Endoscopy*. 2012 Feb;44(2):210-2.
36. Larson DE, Burton DD, Schroeder KW, DiMagno EP. Percutaneous endoscopic gastrostomy. Indications, success, complications, and mortality in 314 consecutive patients. *Gastroenterology*. 1987 Jul;93(1):48-52.
37. Ljungdahl M, Sundbom M. Complication rate lower after percutaneous endoscopic gastrostomy than after surgical gastrostomy: a prospective, randomized trial. *Surg Endosc*. 2006 Aug;20(8):1248-51.
38. DeLegge, Mark H., et al. "Percutaneous endoscopic gastrojejunostomy: a dual center safety and efficacy trial." *Journal of Parenteral and Enteral Nutrition*. 1995;19: 239-243.
39. Hallisey MJ, Pollard JC. Direct percutaneous jejunostomy. *J Vasc Interv Radiol*. 1994 Jul-Aug;5(4):625-32.
40. van Overhagen H, Ludviksson MA, Laméris JS, Zwamborn AW, Tilanus HW, Dees J, Hansen BE. US and fluoroscopic-guided percutaneous jejunostomy: experience in 49 patients. *J Vasc Interv Radiol*. 2000 Jan;11(1):101-6.
41. Cope C, Davis AG, Baum RA, Haskal ZJ, Soulen MC, Shlansky-Goldberg RD. Direct percutaneous jejunostomy: techniques and applications--ten years experience. *Radiology*. 1998 Dec;209(3):747-54.
42. Sarr MG. Appropriate use, complications and advantages demonstrated in 500 consecutive needle catheter jejunostomies. *Br J Surg*. 1999 Apr;86(4):557-61.
43. Holmes JH 4th, Brundage SI, Yuen P, Hall RA, Maier RV, Jurkovich GJ. Complications of surgical feeding jejunostomy in trauma patients. *J Trauma*. 1999 Dec;47(6):1009-12.
44. Han-Geurts, I. J. M., et al. Laparoscopic feeding jejunostomy: a systematic review. *Surgical Endoscopy And Other Interventional Techniques*. 2005; 19: 951-957.