


Endoscopic Ultrasound Guided Intervention for Gastric Variceal Bleeding



Larissa L. Fujii-Lau



Louis M. Wong Kee Song



Michael J. Levy

Acute hemorrhage from gastric varices (GV) is more severe and difficult to treat, often leading to a poorer patient prognosis, as compared to esophageal varices (EV). Currently, the recommended treatment of bleeding GV is endoscopic cyanoacrylate injection. Endoscopic ultrasound (EUS) may enhance variceal detection and improve therapeutic targeting. Newer endosonographic techniques have been developed to offer an alternative treatment and improve patient outcome. This article serves to review these EUS techniques used to treat GV.

INTRODUCTION

Gastric varices (GV) are found in up to 20% of patients with portal hypertension.¹ Approximately 5% of GV will have clinically-evident bleeding.² Acute hemorrhage from GV occurs less frequently than esophageal varices (EV), but is more severe and often requires more blood transfusions.¹

Soehendra et al. in 1986 reported on cyanoacrylate (glue) injection of GV, representing an important breakthrough in the endoscopic treatment of GV.³ Subsequently, many studies have demonstrated the efficacy of GV obliteration using cyanoacrylate injection. Despite the lack of large randomized control trials, current practice guidelines and expert consensus

recommend the use of glue injection to treat GV.^{4,5}

Endoscopic ultrasound (EUS) has been increasingly used as a therapeutic procedure, allowing precise targeting of structures. EUS-guided angiotherapy is an example of the growing practice of interventional EUS. Due to the lack of prospective randomized control trials comparing EUS and conventional endoscopic therapy, the use of EUS-guided therapy has been limited to few institutions. EUS may enhance variceal detection and improve targeting of therapy, particularly in patients in whom endoscopic treatments were ineffective due to failed therapy or the inability to adequately visualize the varices (e.g. subepithelial component). This review serves to highlight novel EUS techniques which have emerged as alternatives to standard glue injection for the treatment of GV.

Larissa L. Fujii-Lau, M.D., Louis M. Wong Kee Song, M.D., Michael J. Levy, M.D., Division of Gastroenterology and Hepatology, Mayo Clinic, Rochester, MN

Figure 1. 51 Year Old Female with Gastric Varices (GOV2)

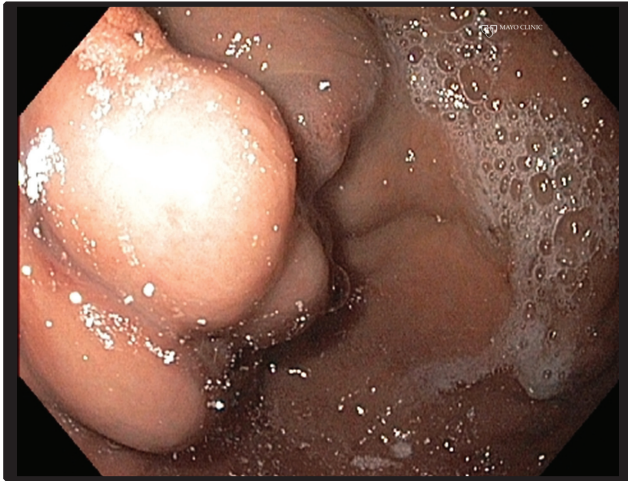

Figure 1a. Endoscopy revealed gastric varices

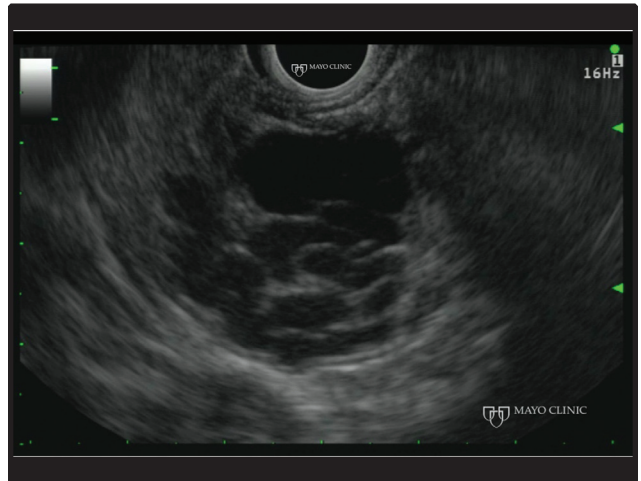


Figure 1b. EUS grey scale appearance of the gastric varices

EUS Detection of Gastric Varices

EUS-guided therapy of GV offers several potential advantages over conventional endoscopic treatment, including enhanced diagnosis, treatment, and follow-up. As EUS images deep to the mucosal lining, it has a higher sensitivity for variceal detection,³³ particularly GV which often have a significant submucosal component.³⁴ In addition, EUS may visualize the entire variceal complex as well as the feeding and perforating vessels, which allows direct targeting of these sites. This is important as the risk of recurrent varices and hemorrhage have been shown to correlate with number of varices, their diameter, and the persistence of flow.³⁵⁻³⁷ The use of Doppler before and after the injection of coils and/or cyanoacrylate allows monitoring of the treatment success.

EUS-Guided Coil Injection

Technique

In our practice, all EUS angiotherapy procedures are performed using a curvilinear echoendoscope with fluoroscopic assistance. Due to the length and complexity of the procedure, general anesthesia should be considered. Prophylactic antibiotics should be administered if a vessel is punctured through the gut lumen, with the use of post-procedure antibiotics advocated by some.

After identification of GV using a curvilinear echoendoscope, color or power Doppler should be used to anatomically delineate the variceal network with the

goal of targeting either the feeding vessel for localized GV or the largest vein in diffuse GV. (Figure 1a-f) Once the target vessel is identified, a fine needle aspiration (FNA) needle is loaded with a coil. We prefer using a 22-gauge FNA needle to allow for 0.018 inch coils rather than larger needles and coils due to the ease of administration and potentially decreased risk of bleeding at the needle puncture site. The coiled diameter of the coil should be approximately 1.25-1.5 times the diameter of the targeted vessel, which typically results in use of 6-10 mm (straight length 70-140 mm) coiled diameters. We remove the stylet from the FNA needle and use the stylet to advance the coil until it lies just short of the needle tip. While some use a guidewire to advance the coil, we prefer use of the stiffer stylet which incurs no additional cost. Once the coil is loaded, the FNA needle is inserted through the echoendoscope channel and then advanced into the vessel. We typically puncture through the entire vessel and a short distance into deeper structures to anchor the coil. We then slowly advance the stylet to deliver the coil and minimally retract the needle to allow the coil to predominantly lie within the vessel itself. Finally, we often anchor a portion of the coil at the side of the vessel that lies closest to the echoendoscope. Throughout the procedure both endosonographic and fluoroscopic images are continuously monitored to ensure proper coil placement. Doppler should be performed to document the decreased blood flow and potential need for additional therapy.

(continued on page 50)

(continued from page 44)

Clinical Application

One group has reported on EUS-guided coil injection only for GV.⁴⁰ In 4 patients with cirrhosis-related GV, coil embolization was performed with eradication of GV in 3 (75%) cases. The first patient had 13 coils inserted throughout the GV complex, followed by 9 coils placed into a 13 mm perforating vessel. The subsequent 3 patients had 2-7 coils placed only into the perforating vessel, which ranged from 6-12 mm in size. No coils migrated in the 5 months of follow-up.

The same group recently described a multicenter retrospective analysis on the use of coils versus cyanoacrylate to treat GV.³⁹ Due to its retrospective and non-randomized nature, the 2 groups should be compared cautiously. In the coil embolization only group, in which it is unclear whether some patients from their initial study were included, complete obliteration of the GV by injection into the perforating vein occurred in 10 of 11 patients (91%). Majority of cases had complete treatment of the perforating vessel within 1 session (9 patients; 82%). A mean of 5.8 (SD 1.2) coils were placed per patient. Although more patients required subsequent procedures in the cyanoacrylate group compared to the coil group, the authors commented that the endosonographers thought that coil injection was more technically demanding.

Our single-institution experience with EUS-guided coil injection into GV encompasses 3 patients with

underlying cirrhosis, malignant portal hypertension, or portal vein thrombosis. These patients underwent a total of 6 procedures with total of 14, 9, and 7 coils placed. In all 3 patients, there was no evidence of further GV bleeding after coil embolization during a median follow-up of 17 months. Two patients had bleeding episodes related to EV after obliteration of the GV complex, therefore these patients may benefit from endoscopic surveillance and treatment of EV after successful therapy of the GV.

EUS-Guided Cyanoacrylate Injection

Technique

Similar to coil injection, the targeted vessel should be thoroughly mapped using the EUS prior to cyanoacrylate injection. Only after careful planning of the projected glue insertion would we recommend preloading the FNA needle with cyanoacrylate in order to minimize the risk of glue occlusion within the needle. This technique is preferred over using the stylet during vessel puncture and subsequent removal of the stylet before the glue is loaded into the needle, which may increase the risk of withdrawing blood into the needle and insertion of a clot or air as the glue is then inserted through the needle. We use a 1:1 mixture of 2-octyl cyanoacrylate and lipiodol to allow for fluoroscopic monitoring during glue injection. As the risk of embolization increases with the volume of cyanoacrylate injected, it is recommended to use the least amount of glue possible to achieve decreased flow

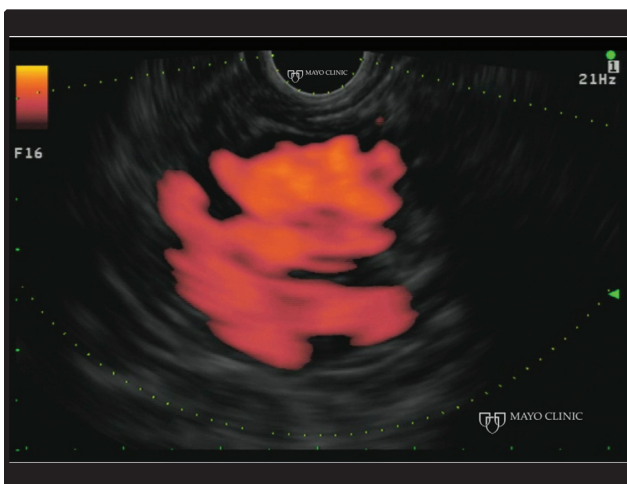


Figure 1c. EUS power Doppler appearance of the gastric varices

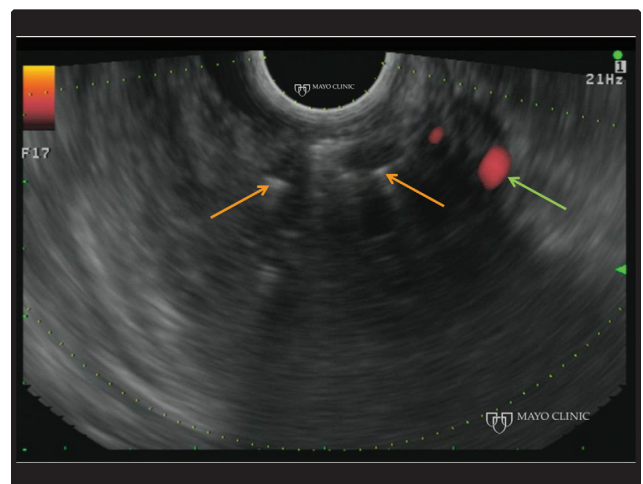


Figure 1d: EUS demonstrates the microcoils (orange arrows) and the near complete resolution of blood flow (green arrow)

through the variceal complex.²⁹ As there is a high cost of repairing an echoendoscope if glue becomes lodged within the channel, extreme care must be undertaken to immediately clean the echoendoscope thoroughly after each cyanoacrylate injection.

Clinical application

The first study on the utility of EUS-guided cyanoacrylate injection compared a historical group of patients who underwent conventional endoscopic glue injection during an acute GV bleeding episode with a group who underwent endoscopic glue injection during the acute hemorrhage followed by EUS surveillance and further glue injection until eradication.⁴¹ Primary hemostasis during the initial endoscopic procedure occurred in >95% of patients in both groups. The EUS group underwent an average of 2.2 (SD 1.7) procedures to completely obliterate GV in 43 of 54 patients (80%). No adverse events were reported during the EUS-guided injection. Those in the EUS surveillance group had significantly fewer episodes of recurrent GV bleeding as compared to those who received conventional endoscopic glue injection (26% vs 57%, $p=0.002$). Although the use of a historical cohort is not an ideal method to compare treatment strategies, this study introduced the concept that patients with a history of active GV hemorrhage may benefit from EUS surveillance and treatment of persistent GV to decrease the risk of rebleeding.

A case series on 5 patients with cirrhosis-related GV who underwent EUS-guided cyanoacrylate injection

into a perforating vessel showed complete obliteration in all the patients after injecting a mean of 1.6 mL of glue.⁴² During a mean follow-up of 10 months, no adverse events or recurrent bleeding were observed. Focusing on the patients who underwent only EUS-guided glue embolization by the same authors in the study mentioned in the EUS-guided coil injection section, all 19 patients had complete obliteration of the feeding gastric vessel.³⁹ The 5 patients reported in the initial case series were not included in the subsequent study. Only 42% of patients had successful treatment after 1 session of EUS-guided glue injection. A mean of 1.5 (SD 0.1) mL of cyanoacrylate was injected per patient. Although 12 adverse events occurred in 11 patients in the cyanoacrylate group, only 2 were symptomatic including fever ($n=1$) and chest pain ($n=1$). There were 9 asymptomatic pulmonary glue embolisms (47%) detected on routine chest CT scans performed in all patients in the EUS-guided glue injection group, which significantly lengthened their hospital stay.

EUS-Guided Combined Coil and Cyanoacrylate Injection

The injection of coils prior to glue theoretically provides a scaffold and helps anchor the glue, which may decrease the risk of embolization.³⁸ Binmoeller et al. described an ex-vivo experiment where a 1 mL of cyanoacrylate was injected into heparinized blood that contained a previously placed coil.³⁸ The glue clung to the fibers of the coil, allowing all of the glue to be

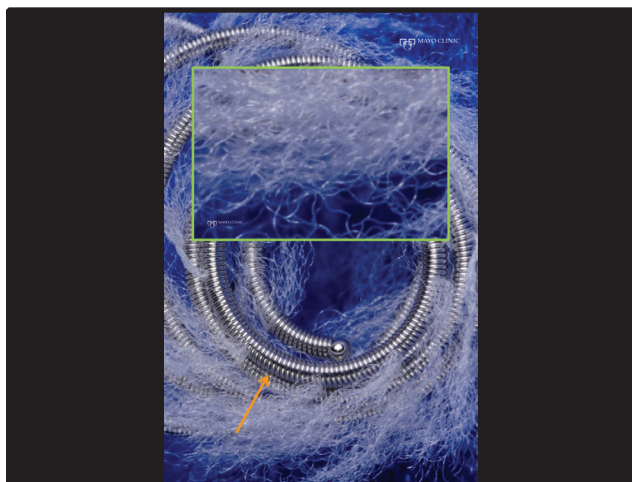


Figure 1e: Magnified view of microcoils demonstrating the metallic coil design (orange arrow) and synthetic fibers that help promote hemostasis (green square).

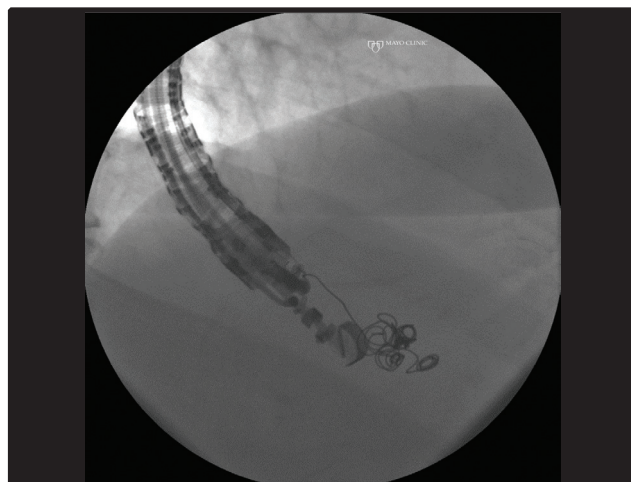


Figure 1f. Fluoroscopic view of the coils

removed with the coil in a single piece. Therefore, it was hypothesized that EUS-guided coil insertion followed by cyanoacrylate injection improves variceal obliteration while decreasing the risk of glue embolization.

The same group retrospectively analyzed 30 patients with acute or recent (<1 week) bleeding from GV who underwent EUS-guided coil and glue embolization of a feeding vessel.⁴³ Technical success of coil and glue injection occurred in all 30 patients, while immediate hemostasis was achieved in both patients with active bleeding. The majority (93%) of cases only had 1 coil placed and a mean of 1.4 mL of 2-octyl-cyanoacrylate was injected. No immediate adverse events, including clinical evidence of pulmonary glue embolisms, occurred. Of those with subsequent surveillance endoscopy, 96% had complete obliteration of the feeding vessel and no evidence of flow on color Doppler within the variceal complex. One patient had recurrent GV bleeding 21 days after the initial procedure, which was treated with a subsequent EUS-guided combined coil and glue injection. At follow-up endoscopies, the glue and coils were found to spontaneously extrude into the stomach and eventually form a scar. Prospective trials are needed to confirm the theoretical benefit of using coils to anchor the glue.

EUS-Guided Portosystemic Gradient Measurement and Shunt Placement

In patients whom the underlying cause of GV is unclear, a hepatic venous pressure gradient (HVPG) obtained via transjugular access may be required for the diagnosis of portal hypertension. Although the HVPG is an accurate surrogate marker for sinusoidal and post-sinusoidal portal hypertension, pre-sinusoidal disease is not often diagnosed due to the inability of the wedge hepatic vein pressure to accurately approximate the portal vein pressure. Therefore, direct portal pressure measurements may be required in these situations. Percutaneous direct portal vein access is challenging and carries a significant risk, so several centers have reported on the use of EUS-guided portal vein catheterization and pressure measurement in porcine models.[Lai et al., Giday et al.] Portal pressure measurement was successful in all pigs, and was shown to correlate with transabdominal ultrasound-guided transhepatic portal vein pressure measurement ($r=0.91$). We performed the first EUS-guided portosystemic pressure gradient in a human subject to help rule-out portal hypertension as the cause of the patient's recurrent gastrointestinal bleeding

from duodenal varices. The portal vein was accessed transduodenally with a 22-gauge fine needle aspiration (FNA) needle (Wilson-Cook Medical Inc., Winston-Salem, NC) and contrast injection under fluoroscopy confirmed vascular access with a blush of contrast that quickly disappeared. Portal blood was then aspirated through the needle, which was connected to an arterial line pressure catheter, and portal pressure was measured after calibration. The same technique was repeated after identification and transgastric puncture of the middle hepatic vein. The portal vein, hepatic vein, and portosystemic pressure gradient all correlated with prior interventional radiology measurements of the HVPG.

Transjugular intrahepatic portosystemic shunts (TIPS) are performed by interventional radiologists when a patient has recurrent or refractory variceal bleeding. In the future, EUS-guided portosystemic shunt placement may be an option, particularly during the same session in which other EUS interventions have been unsuccessful. One experimental study on 10 live porcine models used a linear echoendoscope to identify intrahepatic branches of the portal vein and hepatic vein.⁴⁴ A 19-gauge needle was inserted transgastrically into an intrahepatic branch of the hepatic vein, and then advanced through normal liver parenchyma into a nearby intrahepatic branch of the portal vein. Venography was performed under fluoroscopic guidance to confirm position, followed by insertion of a 0.035-inch guidewire. After removal of the echoendoscope, a covered Zilver biliary self-expandable metal stent (ZILBS; Cook Endoscopy; Winston-Salem, NC) was inserted over the wire and deployed while monitoring fluoroscopic and endosonographic images. The chosen stent was 1-2 cm longer than the distance from the punctured hepatic vein to portal vein and the diameter approximated the diameter of the portal vein. Repeat venography was performed to confirm adequate placement. Four animals required an additional stent to be placed as the initial stent was not long enough to cover the intended distance. No adverse events occurred in any animal. Additional studies are required to understand the role and outcomes of EUS-guided portosystemic shunt placement in human subjects.

SUMMARY

Bleeding from GV remains a challenge for the endoscopist. Although the recommended treatment is endoscopic glue injection, novel approaches and

(continued on page 54)

(continued from page 52)

techniques are being studied to improve outcomes in these patients. As most studies on these emerging modalities are limited to case series, additional research is required to determine the optimal treatment option for patients with GV hemorrhage. In addition, additional trials focusing only on the treatment of fundal varices are needed to determine the long-term outcomes of these therapies. Ultimately, the decision on how to treat GV will largely depend on local expertise and should be approached in a multidisciplinary manner incorporating standard endoscopy, EUS, and interventional radiology. ■

References

- Sarin SK, Lahoti D, Saxena SP, Murthy NS, Makwana UK. Prevalence, classification and natural history of gastric varices: a long-term follow-up study in 568 portal hypertension patients. *Hepatology* 1992;16:1343-9.
- Sarin SK, Kumar A. Gastric varices: profile, classification, and management. *The American journal of gastroenterology* 1989;84:1244-9.
- Soehendra N, Nam VC, Grimm H, Kempeneers I. Endoscopic obliteration of large esophagogastric varices with bucrylate. *Endoscopy* 1986;18:25-6.
- Garcia-Tsao G, Sanyal AJ, Grace ND, Carey WD. Prevention and management of gastroesophageal varices and variceal hemorrhage in cirrhosis. *The American journal of gastroenterology* 2007;102:2086-102.
- de Franchis R. Revising consensus in portal hypertension: report of the Baveno V consensus workshop on methodology of diagnosis and therapy in portal hypertension. *Journal of hepatology* 2010;53:762-8.
- Arakawa M, Masuzaki T, Okuda K. Pathology of fundic varices of the stomach and rupture. *Journal of gastroenterology and hepatology* 2002;17:1064-9.
- Sarin SK, Mishra SR. Endoscopic therapy for gastric varices. *Clinics in liver disease* 2010;14:263-79.
- Ryan BM, Stockbrugger RW, Ryan JM. A pathophysiologic, gastroenterologic, and radiologic approach to the management of gastric varices. *Gastroenterology* 2004;126:1175-89.
- Korula J, Chin K, Ko Y, Yamada S. Demonstration of two distinct subsets of gastric varices. Observations during a seven-year study of endoscopic sclerotherapy. *Digestive diseases and sciences* 1991;36:303-9.
- Trudeau W, Prindiville T. Endoscopic injection sclerosis in bleeding gastric varices. *Gastrointestinal endoscopy* 1986;32:264-8.
- Chang KY, Wu CS, Chen PC. Prospective, randomized trial of hypertonic glucose water and sodium tetradecyl sulfate for gastric variceal bleeding in patients with advanced liver cirrhosis. *Endoscopy* 1996;28:481-6.
- Sarin SK. Long-term follow-up of gastric variceal sclerotherapy: an eleven-year experience. *Gastrointestinal endoscopy* 1997;46:8-14.
- Schuman BM, Beckman JW, Tedesco FJ, Griffin JW, Jr., Assad RT. Complications of endoscopic injection sclerotherapy: a review. *The American journal of gastroenterology* 1987;82:823-30.
- Garcia-Tsao G, Sanyal AJ, Grace ND, Carey W. Prevention and management of gastroesophageal varices and variceal hemorrhage in cirrhosis. *Hepatology* 2007;46:922-38.
- Lo GH, Lai KH, Cheng JS, Chen MH, Chiang HT. A prospective, randomized trial of the butyl cyanoacrylate injection versus band ligation in the management of bleeding gastric varices. *Hepatology* 2001;33:1060-4.
- Tan PC, Hou MC, Lin HC, Liu TT, Lee FY, Chang FY, Lee SD. A randomized trial of endoscopic treatment of acute gastric variceal hemorrhage: N-butyl-2-cyanoacrylate injection versus band ligation. *Hepatology* 2006;43:690-7.
- Tantau M, Crisan D, Popa D, Vesa S, Tantau A. Band ligation vs. N-Butyl-2-cyanoacrylate injection in acute gastric variceal bleeding: a prospective follow-up study. *Annals of hepatology* 2013;13:75-83.
- Nguyen AJ, Baron TH, Burgart LJ, Leontovich O, Rajan E, Gostout CJ. 2-Octyl-2-cyanoacrylate (Dermabond), a new glue for variceal injection therapy: results of a preliminary animal study. *Gastrointestinal endoscopy* 2002;55:572-5.
- Wang YM, Cheng LF, Li N, Wu K, Zhai JS, Wang YW. Study of glue extrusion after endoscopic N-butyl-2-cyanoacrylate injection on gastric variceal bleeding. *World journal of gastroenterology* : WJG 2009;15:4945-51.
- Seewald S, Ang TL, Imazu H, Naga M, Omar S, Groth S, Seitz U, Zhong Y, Thonke F, Soehendra N. A standardized injection technique and regimen ensures success and safety of N-butyl-2-cyanoacrylate injection for the treatment of gastric fundal varices (with videos). *Gastrointestinal endoscopy* 2008;68:447-54.
- Rao AS, Misra S, Buttar NS, Baron TH, Wong Kee Song LM. Combined endoscopic-interventional radiologic approach for the treatment of bleeding gastric varices in the setting of a large splenorenal shunt. *Gastrointestinal endoscopy* 2012;76:1064-5.
- Huang YH, Yeh HZ, Chen GH, Chang CS, Wu CY, Poon SK, Lien HC, Yang SS. Endoscopic treatment of bleeding gastric varices by N-butyl-2-cyanoacrylate (Histoacryl) injection: long-term efficacy and safety. *Gastrointestinal endoscopy* 2000;52:160-7.
- Akahoshi T, Hashizume M, Shimabukuro R, Tanoue K, Tomikawa M, Okita K, Gotoh N, Konishi K, Tsutsumi N, Sugimachi K. Long-term results of endoscopic Histoacryl injection sclerotherapy for gastric variceal bleeding: a 10-year experience. *Surgery* 2002;131:S176-81.
- Dhiman RK, Chawla Y, Taneja S, Biswas R, Sharma TR, Dilawari JB. Endoscopic sclerotherapy of gastric variceal bleeding with N-butyl-2-cyanoacrylate. *Journal of clinical gastroenterology* 2002;35:222-7.
- Kang EJ, Jeong SW, Jang JY, Cho JY, Lee SH, Kim HG, Kim SG, Kim YS, Cheon YK, Cho YD, Kim HS, Kim BS. Long-term result of endoscopic Histoacryl (N-butyl-2-cyanoacrylate) injection for treatment of gastric varices. *World journal of gastroenterology* : WJG 2011;17:1494-500.
- Sarin SK, Jain AK, Jain M, Gupta R. A randomized controlled trial of cyanoacrylate versus alcohol injection in patients with isolated fundic varices. *The American journal of gastroenterology* 2002;97:1010-5.
- Oho K, Iwao T, Sumino M, Toyonaga A, Tanikawa K. Ethanolamine oleate versus butyl cyanoacrylate for bleeding gastric varices: a nonrandomized study. *Endoscopy* 1995;27:349-54.
- Cheng LF, Wang ZQ, Li CZ, Lin W, Yeo AE, Jin B. Low incidence of complications from endoscopic gastric variceal obturation with butyl cyanoacrylate. *Clinical gastroenterology and hepatology* : the official clinical practice journal of the American Gastroenterological Association 2010;8:760-6.
- Hwang SS, Kim HH, Park SH, Kim SE, Jung JI, Ahn BY, Kim SH, Chung SK, Park YH, Choi KH. N-butyl-2-cyanoacrylate pulmonary embolism after endoscopic injection

- tion sclerotherapy for gastric variceal bleeding. *Journal of computer assisted tomography* 2001;25:16-22.
30. Sung JJ, Luo D, Wu JC, Ching JY, Chan FK, Lau JY, Mack S, Ducharme R, Okolo P, Canto M, Kalloo A, Giday SA. Early clinical experience of the safety and effectiveness of Hemospray in achieving hemostasis in patients with acute peptic ulcer bleeding. *Endoscopy* 2011;43:291-5.
 31. Stanley AJ, Smith LA, Morris AJ. Use of hemostatic powder (Hemospray) in the management of refractory gastric variceal hemorrhage. *Endoscopy* 2013;45 Suppl 2 UCTN:E86-7.
 32. Holster IL, Poley JW, Kuipers EJ, Tjwa ET. Controlling gastric variceal bleeding with endoscopically applied hemostatic powder (Hemospray). *Journal of hepatology* 2012;57:1397-8.
 33. Boustiere C, Dumas O, Jouffre C, Letard JC, Patouillard B, Etaix JP, Barthelemy C, Audigier JC. Endoscopic ultrasonography classification of gastric varices in patients with cirrhosis. Comparison with endoscopic findings. *Journal of hepatology* 1993;19:268-72.
 34. Arakawa M, Masuzaki T, Okuda K. Pathomorphology of esophageal and gastric varices. *Seminars in liver disease* 2002;22:73-82.
 35. Iwase H, Suga S, Morise K, Kuroiwa A, Yamaguchi T, Horiuchi Y. Color Doppler endoscopic ultrasonography for the evaluation of gastric varices and endoscopic obliteration with cyanoacrylate glue. *Gastrointestinal endoscopy* 1995;41:150-4.
 36. Irisawa A, Saito A, Obara K, Shibukawa G, Takagi T, Shishido H, Sakamoto H, Sato Y, Kasukawa R. Endoscopic recurrence of esophageal varices is associated with the specific EUS abnormalities: severe periesophageal collateral veins and large perforating veins. *Gastrointestinal endoscopy* 2001;53:77-84.
 37. Sato T, Yamazaki K, Toyota J, Karino Y, Ohmura T, Akaike J. Endoscopic ultrasonographic evaluation of hemodynamics related to variceal relapse in esophageal variceal patients. *Hepatology research : the official journal of the Japan Society of Hepatology* 2009;39:126-33.
 38. Weilert F, Binmoeller KF. EUS-guided vascular access and therapy. *Gastrointestinal endoscopy clinics of North America* 2012;22:303-14, x.
 39. Romero-Castro R, Ellrichmann M, Ortiz-Moyano C, Subtil-Inigo JC, Junquera-Florez F, Gornals JB, Repiso-Ortega A, Vila-Costas J, Marcos-Sanchez F, Munoz-Navas M, Romero-Gomez M, Brullet-Benedi E, Romero-Vazquez J, Caunedo-Alvarez A, Pellicer-Bautista F, Herrerias-Gutierrez JM, Fritscher-Ravens A. EUS-guided coil versus cyanoacrylate therapy for the treatment of gastric varices: a multicenter study (with videos). *Gastrointestinal endoscopy* 2013;78:711-21.
 40. Romero-Castro R, Pellicer-Bautista F, Giovannini M, Marcos-Sanchez F, Caparros-Escudero C, Jimenez-Saenz M, Gomez-Parra M, Arenzana-Seisdedos A, Leria-Yebenes V, Herrerias-Gutierrez JM. Endoscopic ultrasound (EUS)-guided coil embolization therapy in gastric varices. *Endoscopy* 2010;42 Suppl 2:E35-6.
 41. Lee YT, Chan FK, Ng EK, Leung VK, Law KB, Yung MY, Chung SC, Sung JJ. EUS-guided injection of cyanoacrylate for bleeding gastric varices. *Gastrointestinal endoscopy* 2000;52:168-74.
 42. Romero-Castro R, Pellicer-Bautista FJ, Jimenez-Saenz M, Marcos-Sanchez F, Caunedo-Alvarez A, Ortiz-Moyano C, Gomez-Parra M, Herrerias-Gutierrez JM. EUS-guided injection of cyanoacrylate in perforating feeding veins in gastric varices: results in 5 cases. *Gastrointestinal endoscopy* 2007;66:402-7.
 43. Binmoeller KF, Weilert F, Shah JN, Kim J. EUS-guided transesophageal treatment of gastric fundal varices with combined coiling and cyanoacrylate glue injection (with videos). *Gastrointestinal endoscopy* 2011;74:1019-25.
 44. Buscaglia JM, Dray X, Shin EJ, Magno P, Chmura KM, Surti VC, Dillon TE, Ducharme RW, Donatelli G, Thuluvath PJ, Giday SA, Kantsevov SV. A new alternative for a transjugular intrahepatic portosystemic shunt: EUS-guided creation of an intrahepatic portosystemic shunt (with video). *Gastrointestinal endoscopy* 2009;69:941-7.
 45. Tripathi D, Therapondos G, Jackson E, Redhead DN, Hayes PC. The role of the transjugular intrahepatic portosystemic shunt (TIPSS) in the management of bleeding gastric varices: clinical and haemodynamic correlations. *Gut* 2002;51:270-4.
 46. Chikamori F, Kuniyoshi N, Shibuya S, Takase Y. Correlation between endoscopic and angiographic findings in patients with esophageal and isolated gastric varices. *Digestive surgery* 2001;18:176-81.
 47. Patel A, Fischman AM, Saad WE. Balloon-occluded retrograde transvenous obliteration of gastric varices. *AJR. American journal of roentgenology* 2012;199:721-9.
 48. Saad WE, Kitanosono T, Koizumi J, Hirota S. The conventional balloon-occluded retrograde transvenous obliteration procedure: indications, contraindications, and technical applications. *Techniques in vascular and interventional radiology* 2013;16:101-51.
 49. Sabri SS, Abi-Jaoudeh N, Swee W, Saad WE, Turba UC, Caldwell SH, Angle JF, Matsumoto AH. Short-term rebleeding rates for isolated gastric varices managed by transjugular intrahepatic portosystemic shunt versus balloon-occluded retrograde transvenous obliteration. *Journal of vascular and interventional radiology : JVIR* 2014;25:355-61.
 50. Akahoshi T, Hashizume M, Tomikawa M, Kawanaka H, Yamaguchi S, Konishi K, Kinjo N, Maehara Y. Long-term results of balloon-occluded retrograde transvenous obliteration for gastric variceal bleeding and risky gastric varices: a 10-year experience. *Journal of gastroenterology and hepatology* 2008;23:1702-9.

PRACTICAL GASTROENTEROLOGY

VISIT US

AT BOOTH

#705 AT ACG

practicalgastro.com