

Colonic Polypoid Ganglioneuroma

by Saire Mendoza M., Parajuli D.

INTRODUCTION

Intestinal ganglioneuromas can be found throughout the gastrointestinal tract and have three different presentations. They have been reported to be associated with multiple endocrine neoplasia type IIB (MEN-IIB), even before the GI endocrine neoplasms are diagnosed,¹ and occasionally with Von Recklinghausen's disease (VRD).^{2,3} These benign tumors are the result of submucosal (nerve) plexus hyperplasia in the intestinal wall,⁴ and consist of ganglion cells, nerve fibers and supporting cells. We report a case of a colonic ganglioneuroma found incidentally on screening colonoscopy. Management of these lesions, the risk of gastrointestinal malignancy and further assessment for occult non-gastrointestinal malignancies will be reviewed.

CASE

An otherwise healthy 69 year-old African American male underwent screening colonoscopy. A 1 cm subepithelial lesion, which was not characteristically adenomatous under both white light and narrow band imaging, was seen at the recto sigmoid junction (Figure 1). This lesion was biopsied and tattooed for future location. The initial sample did not yield a pathologic diagnosis thus rectal endoscopic ultrasound was performed. The lesion was noted to be hypoechoic and arising from the submucosa layer (Figure 2). Bite-on-bite cold forceps biopsies

were taken and sent for histologic examination. The final pathologic findings were reported as a polypoid ganglioneuroma (Figure 3).

DISCUSSION

Intestinal ganglioneuromatous disease (GN) is divided into three groups.

1. Polypoid ganglioneuromas are small (<2cm), sessile or pedunculated polyps that are endoscopically difficult to distinguish from juvenile, hyperplastic or adenomatous polyps. Microscopically, they are divided into three patterns with disarranged crypt architecture with spindle and nerve ganglion cells within the mucosa being the most common.
2. Ganglioneuromatous polyposis (GP) consists of numerous, often 20 to 40, sessile or pedunculated lesions. There is less demarcation among the contents that make up the ganglioneuromas in this subgroup.
3. Diffuse ganglioneuromatosis (DG) presents as disseminated, nodular, intramural or transmural lesions ranging from 1 to 17cm in size and can lead to segmental bowel strictures; histologically these lesions involve the myenteric plexus. Most of DG cases are associated with MEN-IIB or VRD^{3,5,6}; and may radiographically resemble Crohn's disease on barium studies and computed tomography scans⁷

Saire Mendoza M.¹ Parajuli D.² ¹Section of Gastroenterology and Hepatology, Ochsner Medical Center ²Division of Gastroenterology, Hepatology and Nutrition, University of Louisville

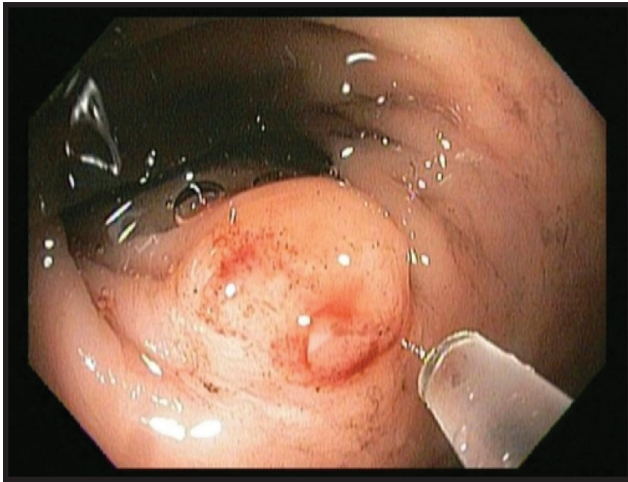


Figure 1. Endoscopic image of the submucosal lesion

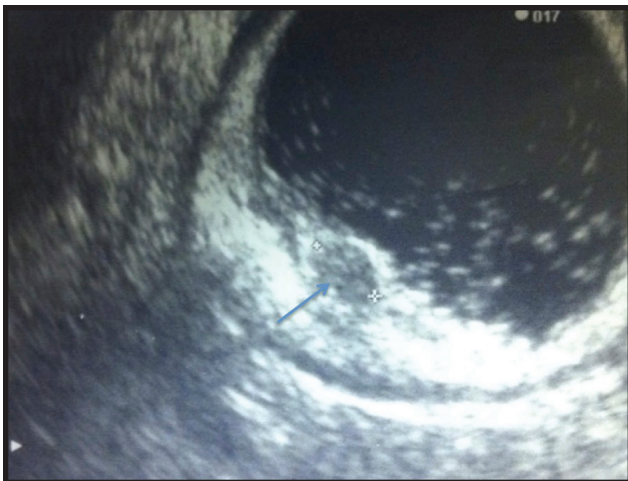

Figure 2. Endoscopic Ultrasound view. Arrow shows a hypoechoic lesion arising off the submucosa layer

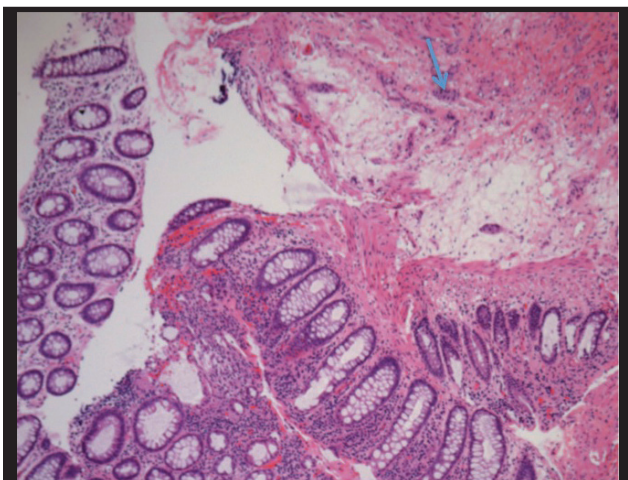


Figure 3. Polypoid Ganglioneuromatosis, colon. Mucosa and scattered isolated nest of ganglion cell (arrow). Hematoxylin and Eosin. x 10.

The largest case series of ganglioneuromatosis was reported by Shekitka et al.³ in 1994 where 43 patients with intestinal ganglioneuromatous disease were followed. While some patients presented with abdominal pain, rectal bleeding or megacolon, many were asymptomatic. However, cases with watery diarrhea secondary to vasoactive intestinal polypeptide secretion and diffuse ganglioneuromatosis involving the colon and rectum have been reported,^{8,9} as well as upper GI bleeding from a ganglioneuroma of the duodenum¹⁰ and polypoid GN causing colonic intussusception.¹¹

The prevalence of diffuse ganglioneuromatosis in patients with MEN-IIB syndrome is nearly 100%, and often gastrointestinal involvement predates the development of medullary thyroid cancer.¹ Diarrhea or constipation from diffuse alimentary tract involvement, was reported in a case series of 16 patients with MEN-IIB.¹ DG was found before medullary thyroid carcinoma in 12 of these 16 cases. Therefore, the authors concluded that diffuse ganglioneuromatosis heralds the development of endocrine neoplasms, especially medullary thyroid carcinoma, which is the most common and most feared component of the MEN-IIB syndrome.

Around 25% of patients with Von Recklinghausen's disease have shown some gastrointestinal involvement, mainly neurofibromas and occasionally ganglioneuromatosis.^{2,5} In one series, the mean interval between diagnosis of Von Recklinghausen's disease and the onset of gastrointestinal symptoms related to gastrointestinal neurofibromatosis was approximately 37 years.² Also, the simultaneous finding of diffuse ganglioneuromatosis and associated adenocarcinoma of the colon in patients with VRD⁵ seems to be more related to the high incidence of adenocarcinoma in patients with Von Recklinghausen's disease¹² rather than secondary to ganglioneuromatosis itself.

Polypoid ganglioneuromatosis and ganglioneuromatosis polyposis do not appear to be associated with systemic disorders such as MEN-IIB or VRD.^{3,6,13,14} Shekita et al.³ followed 16 patients with Polypoid GN and, after eight years, 13 were still alive and did not have evidence of MEN-IIB or VRD. Similar findings were obtained for patients with ganglioneuromatosis polyposis, however, two of the three patients had multiple skin tags and cutaneous tumors which were thought to be lipomas. Chan and colleagues⁶ also reported these cutaneous findings in patients with ganglioneuromatosis polyposis.

A CASE REPORT

Intestinal ganglioneuromatosis has also been found in association with adenomatous, hyperplastic and juvenile type polyps.^{13,15} However, adenomas do not appear to be the prevailing feature in the setting of ganglioneuromatosis.

CONCLUSION

Three patterns of intestinal ganglioneuromatous disease have been described: polypoid ganglioneuromas, ganglioneuromatous polyposis (GP) and diffuse ganglioneuromatosis. Most cases of diffuse ganglioneuromatosis have been associated with MEN- IIB. The clinical presentation depends on size and location of ganglioneuromas. In diffuse ganglioneuromatosis, gastrointestinal symptoms usually precede the development of thyroid medullary neoplasms and should prompt further diagnostic work up. There is not enough literature to suggest that intestinal ganglioneuromatosis has malignant potential.¹⁷ As such, an aggressive surgical approach in an asymptomatic patient without increased risk of carcinoma may be unnecessary.⁷ In the cases where GN is found along with hyperplastic or adenomatous polyps, current standard colonoscopy surveillance recommendations after polypectomy¹⁶ should be followed. ■

Abbreviation

VRD: Von Recklinghausen's disease

Acknowledgement

We thank Dr. Silvia D. Potenziani Pradella from the Department of Pathology and Laboratory Medicine at University of Louisville for contributing images of polypoid ganglioneuromatosis of the colon.

References

1. Carney JA, Go VL, Sizemore GW, Hayles AB. Alimentary-tract ganglioneuromatosis. A major component of the syndrome of multiple endocrine neoplasia, type 2b. *The New England journal of medicine*. Dec 2 1976;295(23):1287-1291.
2. Hochberg FH, Dasilva AB, Galdabini J, Richardson EP, Jr. Gastrointestinal involvement in von Recklinghausen's neurofibromatosis. *Neurology*. Dec 1974;24(12):1144-1151.
3. Shekitka KM, Sobin LH. Ganglioneuromas of the gastrointestinal tract. Relation to Von Recklinghausen disease and other multiple tumor syndromes. *The American journal of surgical pathology*. Mar 1994;18(3):250-257.
4. Feichter S, Meier-Ruge WA, Bruder E. The histopathology of gastrointestinal motility disorders in children. *Seminars in pediatric surgery*. Nov 2009;18(4):206-211.
5. Tomita H, Miya K, Tanaka H, Shimokawa K. Ganglioneuroma and adenocarcinoma associated with neurofibromatosis type 1 in the colorectal region. *International journal of colorectal disease*. Jan 2006;21(1):89-91.

6. Chan OT, Haghighi P. Hamartomatous polyps of the colon: ganglioneuromatous, stromal, and lipomatous. *Archives of pathology & laboratory medicine*. Oct 2006;130(10):1561-1566.
7. Carter JE, Laurini JA. Isolated intestinal neurofibromatous proliferations in the absence of associated systemic syndromes. *World journal of gastroenterology : WJG*. Nov 14 2008;14(42):6569-6571.
8. Moon SB, Park KW, Jung SE, Lee SC. Vasoactive intestinal polypeptide-producing ganglioneuromatosis involving the entire colon and rectum. *Journal of pediatric surgery*. Mar 2009;44(3):e19-21.
9. Rescorla FJ, Vane DW, Fitzgerald JF, West KW, Grosfeld JL. Vasoactive intestinal polypeptide-secreting ganglioneuromatosis affecting the entire colon and rectum. *Journal of pediatric surgery*. Jul 1988;23(7):635-637.
10. Freeman BD, Zuckerman GR, Callery MP. Duodenal ganglioneuroma: a rare cause of upper GI hemorrhage. *The American journal of gastroenterology*. Dec 1996;91(12):2626-2627.
11. Soccorso G, Puls F, Richards C, Pringle H, Nour S. A ganglioneuroma of the sigmoid colon presenting as leading point of intussusception in a child: a case report. *Journal of pediatric surgery*. Jan 2009;44(1):e17-20.
12. Zoller ME, Rembeck B, Oden A, Samuelsson M, Angervall L. Malignant and benign tumors in patients with neurofibromatosis type 1 in a defined Swedish population. *Cancer*. Jun 1 1997;79(11):2125-2131.
13. Rafiq S, Hameer H, Sitrin MD. Ganglioneuromatous polyposis associated with juvenile polyps and a tubular adenoma. *Digestive diseases and sciences*. Mar 2005;50(3):506-508.
14. Mendelsohn G, Diamond MP. Familial ganglioneuromatous polyposis of the large bowel. Report of a family with associated juvenile polyposis. *The American journal of surgical pathology*. Jul 1984;8(7):515-520.
15. Weidner N, Flanders DJ, Mitros FA. Mucosal ganglioneuromatosis associated with multiple colonic polyps. *The American journal of surgical pathology*. Oct 1984;8(10):779-786.
16. Lieberman DA, Rex DK, Winawer SJ, et al. Guidelines for colonoscopy surveillance after polypectomy: a consensus update by the US Multi-Society Task Force on Colorectal Cancer. *Gastroenterology* 2012;143:844-857.
17. Snover DC, Weigent CE, Sumner HW. Diffuse mucosal ganglioneuromatosis of the colon associated with adenocarcinoma. *American journal of clinical pathology*. Feb 1981;75(2):225-229.

PRACTICAL GASTROENTEROLOGY

*Celebrating
Over 39 Years
of Service*

www.practicalgastro.com