

Drainage of a Symptomatic Pancreatic Pseudocyst via a Fully Covered Self Expanding Metal Stent (FCSEMS)

by Douglas G. Adler

INTRODUCTION

Symptomatic pancreatic pseudocysts often require treatment with options including endoscopic drainage, surgical drainage, or catheter drainage via interventional radiologists. No approach is universally accepted as ideal for all patients. This case describes the drainage of a symptomatic pancreatic pseudocyst via endoscopy using a fully covered self-expanding metal stent (FCSEMS).

Case Report

An 81 year-old man underwent a laparoscopic left hemicolectomy for a history of recurrent diverticulitis and diverticular bleeding. During the surgery, the pancreas was accidentally traumatized by a surgical trocar. Following the operation, the patient developed acute pancreatitis and a large pseudocyst in the body of the gland. The cyst caused significant extrinsic compression on the stomach with resulting gastric outlet obstruction. The patient was only able to be fed via a nasojejunal tube (Figure 1). Following eight weeks of tube feeding, a computed tomography (CT) scan showed no interval improvement in the overall size of the cyst and the patient was referred for endoscopic drainage.

The cyst was identified by endoscopic ultrasound (EUS) and a 19 gauge fine-needle aspiration (FNA) needle was used to access the cyst (Figure 2). A 0.035” biliary guidewire was passed through the lumen of the

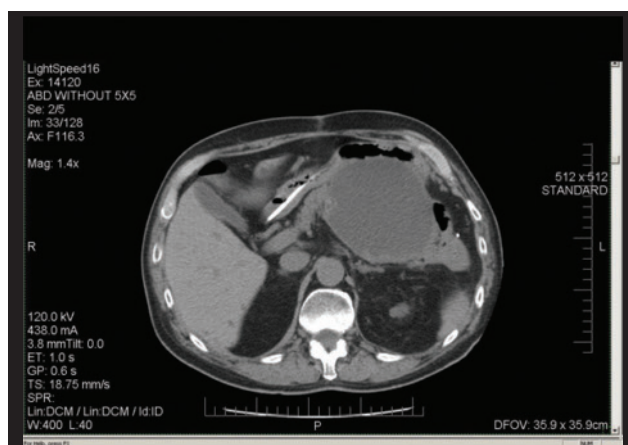


Figure 1. CT scan image showing a large pancreatic pseudocyst compressing the stomach with resulting gastric outlet obstruction. Note nasojejunal tube traversing the stomach.

needle and looped in the cyst. The cystgastrostomy site was dilated with an 8 mm biliary dilating balloon (Figure 3); the location was verified by the flow of cystic fluid into the stomach. A 10 mm x 80 mm fully covered Viabil stent (WL Gore and Associates, Flagstaff, AZ) was then advanced over the guidewire through the EUS scope and deployed across the cystgastrostomy. One half of the stent was deployed in the pseudocyst, and the other half was deployed in the stomach. At this

(continued on page 28)

A CASE REPORT

(continued from page 26)

point copious cyst contents drained into the stomach. Guidewire access to the cyst was then obtained again using a duodenoscope to pass the guidewire through the metal stent and into the cyst. A 7 Fr double pigtail stent was then deployed across the cystgastrostomy, through the metal stent, to serve as an anchor and to reduce the risk of metal stent migration (Figure 4). The patient tolerated the procedure well.

Repeat CT scan obtained four weeks later demonstrated complete resolution of the pseudocyst, with the metal stent/plastic stent complex still in good position (Figure 5). The patient underwent upper endoscopy soon thereafter confirming correct positioning of the stents within a well healed cystgastrostomy site (Figure 6). The plastic stent/metal stent complex was removed in a single pull via rat tooth forceps (Figure 7). The patient has experienced resolution of his gastric outlet obstruction and has no evidence of recurrence of his pseudocyst.

Discussion

Endoscopic drainage of symptomatic pancreatic pseudocysts is widely performed. Cystgastrostomy can be created via endoscopic retrograde cholangiopancreatography (ERCP), EUS, or a combined approach. To date, no ideal approach for all lesions has been identified.^{1,2,3} Most endoscopists who perform these procedures place two or more double pigtail plastic stents across the cystgastrostomy. Plastic stents are inexpensive, and allow the pseudocyst contents to drain both through and between the stents.

The idea of using a metal stent to drain a symptomatic pancreatic pseudocyst is a relatively new concept. Previously, uncovered stents were rarely used for this purpose as there was a fear that such an uncovered device could imbed itself across the cystgastrostomy and might be difficult to remove. The advent of covered biliary metal stents allowed new consideration of using these devices in this context. Metal stents have the advantage of providing a greater diameter through which cyst contents (both solid and liquid) can drain and they offer the benefit of being removable. However, metal stent usage may be limited due to their increased cost.

In a series of ten patients treated with EUS-guided pseudocyst drainage via metal stents, Berzosa et al reported success in nine patients.⁴ Weilert et al used FCSEMS in 18 patients with pancreatic fluid collections,

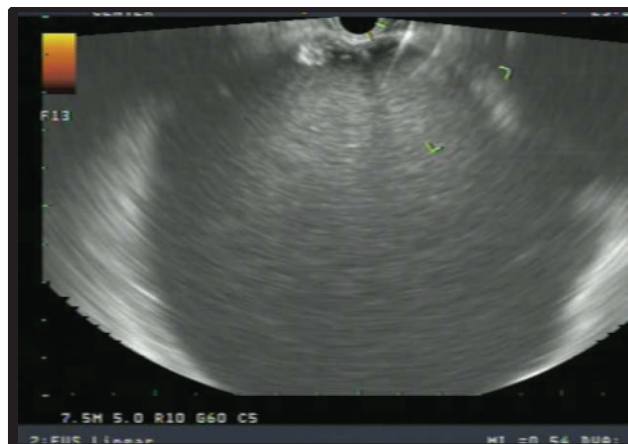


Figure 2. 7.5MHz EUS image of the pseudocyst when viewed from the stomach. There are no interposed vessels and the cyst measured approximately 9cm in greatest diameter.

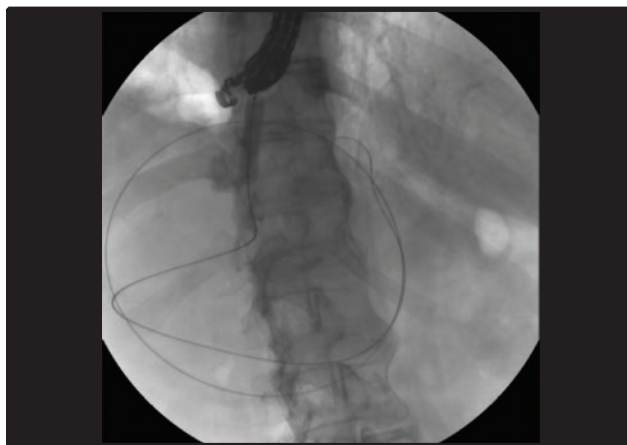


Figure 3. Fluoroscopic view of a biliary dilating balloon filled with contrast and being used to dilate the cystgastrostomy. Note guidewire coiled within pseudocyst lumen.

although they were only left in place for 7-10 days, after which they were removed and replaced with double pigtail stents. Patients in this study had indeterminate adherence of the cyst to the gut lumen and one patient did experience dehiscence of the cystgastrostomy. Overall success in this series was 78% cyst resolution.⁵

The notion of using a covered metal stent to drain a pseudocyst has been extended by some to include walled off pancreatic necrosis. The size of a metal biliary stent may allow an endoscope to pass into the cyst to facilitate endoscopic necrosectomy. Early reports and series using these types of devices are available and are very encouraging.^{6,7}

Recently, dedicated metal stents designed to

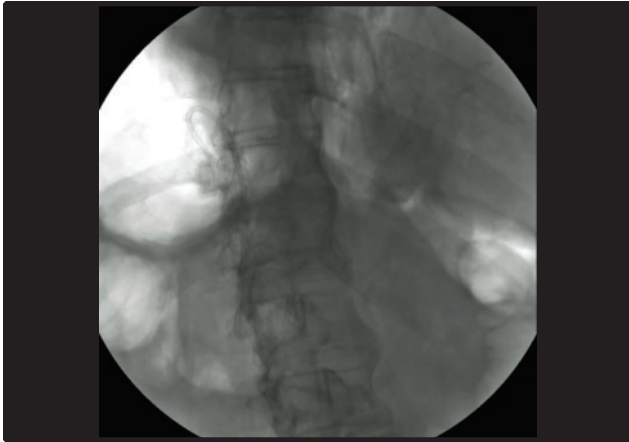


Figure 4a. Fluoroscopic image showing metal stent and plastic stent crossing cystgastrostomy.

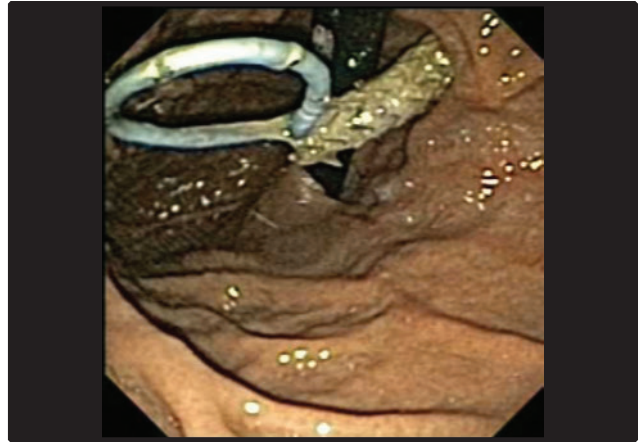


Figure 6. Appearance of the metal stent/plastic stent complex in situ just prior to removal, seen on retroflexion of the endoscope.

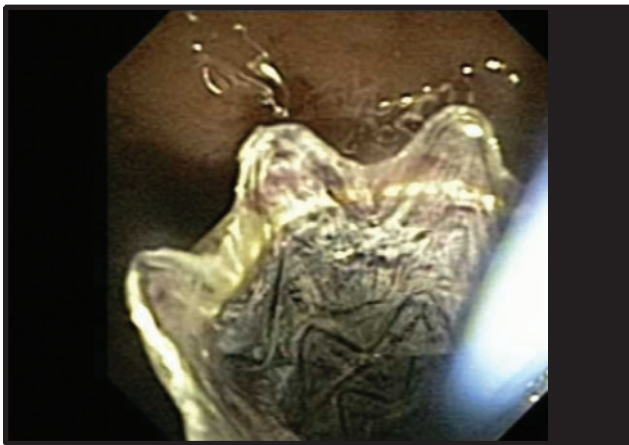


Figure 4b. Endoscopic image of metal stent with plastic stent.



Figure 7. Appearance of the metal stent/plastic stent complex following removal. Note that both stents are patent.

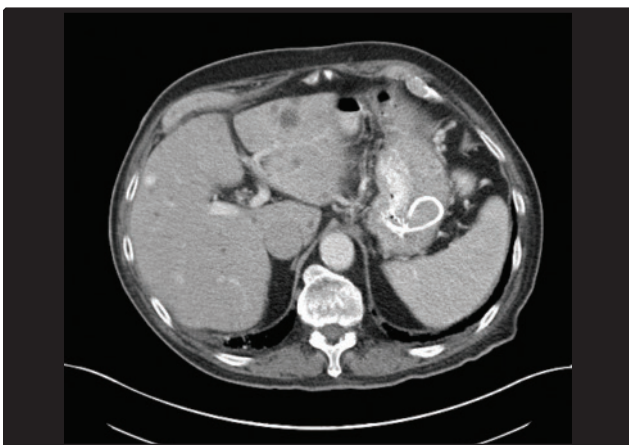


Figure 5. CT scan obtained one month after stent placement. The pseudocyst has resolved and the stents are seen in situ.

facilitate endoscopic drainage of pancreatic fluid collections have become available and the limited data available for these devices is encouraging. These stents have a dumbbell shape to provide flared ends on each side of the cystgastrostomy thus reducing the risk of migration and promoting fixation between the fluid collection and the gut lumen.^{8,9} Itoi et al reported on the use of one of these lumen apposing metal stents to drain 15 patients with symptomatic pancreatic pseudocysts via an EUS-guided approach. In this study, all stents were successfully deployed with a median dwell time of 35 days. One of the metal stents migrated into the stomach, but the others remained in situ across the cystgastrostomy site. All patients had resolution of their pseudocysts.¹⁰

A CASE REPORT

It is difficult to state at this time that metal stents are superior to plastic stents for the drainage of pancreatic pseudocysts and other pancreatic fluid collections.¹¹ Both approaches offer advantages and disadvantages. Migration of a metal stent into a pseudocyst or out into the gut lumen remains a significant risk, and in the case presented above a single double pigtail stent was placed through the metal stent to minimize this risk, although the metal stent used did have antimigration struts built into its matrix. Metal stents can be placed quickly and provide a larger overall lumen for cyst contents to drain, but come at increased cost overall. Removal of both metal and plastic stents appears to be equally easy and straightforward.

The data on using plastic stents to drain pancreatic pseudocysts is far more robust and features large studies to support their use in this context. The data for metal stents in this role is still developing, and it seems likely that larger studies of metal stents in this context will be forthcoming. A randomized trial comparing the two seems would be helpful, and a study comparing plastic stents, biliary metal stents, and specifically designed dumbbell shaped metal stents would be ideal.

CONCLUSION

The use of fully covered metal stents to drain symptomatic pancreatic pseudocysts is becoming more common, and this trend will likely continue to accelerate in clinical practice. FCSEMS appear to be safe and effective in this context, but formal comparisons with plastic stents would be beneficial. Lumen apposing stents are beginning to become more widely available, and it seems likely that these will play a role in any future studies of metal stents in this context. ■

References

1. Howell DA, Holbrook RF, Bosco JJ, et al. Endoscopic needle localization of pancreatic pseudocysts before transmural drainage. *Gastrointest Endosc* 1993;39:693–8.
2. Mönkemüller KE, Baron TH, Morgan DE. Transmural drainage of pancreatic fluid collections without electrocautery using the Seldinger technique. *Gastrointest Endosc* 1998;48:195–200.
3. Kahaleh M, Shami VM, Conaway MR, et al. Endoscopic ultrasound drainage of pancreatic pseudocyst: a prospective comparison with conventional endoscopic drainage. *Endoscopy* 2006;38:355–359.
4. Berzosa M, Maheshwari S, Patel KK, Shaib YH. Single-step endoscopic ultrasonography-guided drainage of peripancreatic fluid collections with a single self-expandable metal stent and standard linear echoendoscope. *Endoscopy*. 2012 May;44(5):543–7. doi: 10.1055/s-0031-1291710. Epub 2012 Mar 9. PubMed PMID:22407382.
5. Weilert F, Binmoeller KF, Shah JN, Bhat YM, Kane S. Endoscopic ultrasound-guided drainage of pancreatic fluid collections with indeterminate adherence using temporary covered metal stents. *Endoscopy*. 2012 Aug;44(8):780–3. doi: 10.1055/s-0032-1309839. Epub 2012 Jul 12. PubMed PMID: 22791588.
6. Itoi T, Nageshwar Reddy D, Yasuda I. New fully-covered self-expandable metal stent for endoscopic ultrasonography-guided intervention in infectious walled-off pancreatic necrosis (with video). *J Hepatobiliary Pancreat Sci*. 2013 Mar;20(3):403–6. doi: 10.1007/s00534-012-0551-5. PubMed PMID: 22926337.
7. Krishnan A, Ramakrishnan R. EUS-guided endoscopic necrosectomy and temporary cystogastrostomy for infected pancreatic necrosis with self-expanding metallic stents. *Surg Laparosc Endosc Percutan Tech*. 2012 Oct;22(5):e319–21. doi: 10.1097/SLE.0b013e3182657e03. PubMed PMID: 23047418.
8. Téllez-Ávila FI, Villalobos-Garita A, Ramírez-Luna MÁ. Use of a novel covered self-expandable metal stent with an anti-migration system for endoscopic ultrasound-guided drainage of a pseudocyst. *World J Gastrointest Endosc*. 2013 Jun 16;5(6):297–9. doi: 10.4253/wjge.v5.i6.297. PubMed PMID: 23772268; PubMed Central PMCID: PMC3680620.
9. Gornals JB, De la Serna-Higuera C, Sánchez-Yague A, Loras C, Sánchez-Cantos AM, Pérez-Miranda M. Endosonography-guided drainage of pancreatic fluid collections with a novel lumen-apposing stent. *Surg Endosc*. 2013 Apr;27(4):1428–34. doi: 10.1007/s00464-012-2591-y. Epub 2012 Dec 12. PubMed PMID:23232994.
10. Itoi T, Binmoeller KF, Shah J, Sofuni A, Itokawa F, Kurihara T, Tsuchiya T, Ishii K, Tsuji S, Ikeuchi N, Moriyasu F. Clinical evaluation of a novel lumen-apposing metal stent for endosonography-guided pancreatic pseudocyst and gallbladder drainage (with videos). *Gastrointest Endosc*. 2012 Apr;75(4):870–6. doi: 10.1016/j.gie.2011.10.020. Epub 2012 Jan 31. PubMed PMID: 22301347.
11. Bang JY, Varadarajulu S. Metal versus Plastic Stent for Transmural Drainage of Pancreatic Fluid Collections. *Clin Endosc*. 2013 Sep;46(5):500–502. Epub 2013 Sep 30. Review. PubMed PMID: 24143311; PubMed Central PMCID: PMC3797934.

PRACTICAL GASTROENTEROLOGY

*Celebrating
Over 38 Years
of Service*

Visit Our Website:

www.practicalgastro.com