

Richard W. McCallum, MD, FACP, FRACP (Aust), FACG, AGAF

Rumination Syndrome: An Update on Diagnostic and Treatment Strategies



Mena Milad



Richard W. McCallum

Rumination syndrome is a disorder characterized by the regurgitation of swallowed food with the decision to re-swallow the material or vomit within minutes after eating. Rumination syndrome can occur as a primary disorder or as a conditioned response in the setting of other vomiting disorders, particularly gastroparesis. This article will focus on the importance of history taking to diagnose rumination syndrome and review treatment strategies including breathing and relaxation skills. In addition, we emphasize a new approach, jejunostomy tube placement in patients with the most severe symptoms.

INTRODUCTION

Rumination syndrome (RS) is a unique, functional gastroenterological disorder characterized by effortless post-prandial regurgitation. The first reports of this syndrome were in the early 17th century culminating with a Mauritian physiologist and neurologist who acquired the condition after swallowing sponges tied to a string to measure gastric pH.^{1,2} This distinct entity has been well described in the recently published Rome IV criteria (Table 1)³ and is diagnosed based on clinical symptoms in the absence of structural disease. Lack of awareness of the disease

often prompts extensive, costly and time-consuming testing and inappropriate medical management without establishing a diagnosis. With understanding of the disease process and of the treatment paradigms, good outcomes and symptom resolution can be achieved.

CASE EXAMPLE

An otherwise healthy 47 year-old Caucasian male presented with a chief complaint of nausea, vomiting and worsening intolerance to oral intake over the past two years. The patient reported that his symptoms started soon after he was robbed at gunpoint followed by a difficult divorce. Careful questioning elicited that he regurgitates his food, recently progressing to water and fluids, within five minutes of eating. He has experienced a 20-pound unintentional weight loss over the two years and has 8-10 emergency department visits annually for nausea and vomiting, abdominal pain, hypokalemia and dehydration. The patient reported that

Mena Milad, MD, Gastroenterology Fellow, Texas Tech University Health Sciences Center
 Richard W. McCallum MD, FACP, FRACP, FACG, AGAF, Department of Internal Medicine, Director, Center for Neurogastroenterology and GI Motility, Texas Tech University, Paul L. Foster School of Medicine El Paso, TX

his emergency department visits have become more frequent with multiple admissions requiring anti-emetics and occasional opioids. None of these admissions were for hematemesis, melena or hematochezia. He has seen multiple physicians, has taken many anti-emetics (including ondansetron, promethazine, metoclopramide as well as hydrocodone-acetaminophen) and recently started using marijuana with some resolution of his symptoms. He experiences gastroesophageal reflux (GERD) after his regurgitation episodes which responds to proton-pump inhibitor (PPI).

As part of the workup prior to his referral, the patient had multiple computed tomography (CT) scans of his abdomen and pelvis and laboratory evaluation [including thyroid stimulating hormone (TSH) levels, early-morning cortisol, complete blood count and complete metabolic profile], all of which were normal. Several gastric emptying studies were attempted, but the patient regurgitated the meals immediately. Upper endoscopy revealed mild esophagitis with a normal stomach and duodenum. Routine biopsies revealed *H. pylori* which was successfully treated.

The diagnosis of rumination syndrome was made based on his symptoms in the setting of a negative evaluation. He was started on nortriptyline, titrated to 50 mg before bed, as well as tramadol for pain control. He was provided with instructions for breathing techniques and tapes for relaxation to precede and accompany eating in order to overcome the rumination reflex. Despite these measures, he continued to present to the emergency department with nausea, vomiting, dehydration and weight loss, and was becoming increasingly depressed. The decision was made to place a jejunostomy feeding tube laparoscopically given his failure to respond to the abovementioned treatments. Gastric wall biopsies taken during the surgery to evaluate the interstitial cells of Cajal as well as the myenteric plexus and smooth muscle were histologically normal.

The patient was placed on nightly tube feeds and daily relaxation and breathing techniques allowing him to slowly increase the content of his diet. He experienced weight gain, while medical and psychological therapy improved his oral intake to ultimately allow jejunostomy tube removal after four months. A four-hour gastric emptying study was then able to be performed and was normal.

EPIDEMIOLOGY

Rumination syndrome (RS) is well recognized in

infants and mentally handicapped individuals with a prevalence between 6 and 10%.⁴ In adults, RS remains an underdiagnosed entity with limited awareness among patients as well as physicians. It is known, however, that RS is more prevalent in young adults with females being more affected than males.⁵

MECHANISMS

Although the exact pathophysiology of RS in humans is not completely understood, it is currently believed to be an unconscious, learned disorder. The rumination episodes involve relaxation of the diaphragm combined with contraction of the abdominal muscles. The lower esophageal sphincter (LES) pressure is overcome by the increase in intraabdominal and intragastric pressure. Initially, this manifests as belching (burping) that evolves into episodes of effortless regurgitation of food and liquids.⁶ Patients have a choice, usually dictated by the social setting, to either vomit the regurgitated material if they are in a place to do so, or re-swallow the material to avoid embarrassment and delay regurgitation until they are in an appropriate setting. This process is voluntary, but not intentional. Patients are unaware that they are contracting their abdominal muscles, which leads to complaints of substantial epigastric abdominal pain. Essentially, the patient is “trapped” in this post-prandial reflex and their stomach has been programmed to respond to oral intake in this manner at every meal, every day.

DIAGNOSIS

A thorough history is important in differentiating RS from other disorders. The average time from onset of symptoms until the diagnosis of RS is approximately 17 months.⁷ Patients undergo expensive, unnecessary, and sometimes invasive testing prior to being diagnosed. Rumination can be a “primary” or a “secondary” disorder associated with states of chronic nausea and vomiting, such as gastroparesis.

The onset of primary rumination syndrome is usually preceded by a stressful life event, such as loss of a family member, job loss, financial hardship, relocation, relationship hardships including divorce and others. Primary rumination syndrome episodes occur daily with each meal. Often patients will avoid or skip meals as they do not wish to vomit in front of family and friends. Over time, the decreased oral intake leads to a gradual weight loss (83%) and dehydration, resulting in visits to the emergency department or primary care

physician.⁷ Hypokalemia is a result of regurgitating acidic, potassium-rich gastric contents in addition to the ingested material. In women with longstanding RS, weight loss can be associated with accompanying amenorrhea, often signaling severe disease. These patients may continue to work but over time cannot sustain the stamina to do so. Diagnostic testing may be limited since it can be difficult to obtain a gastric emptying study in patients with rumination because they often vomit the meal immediately or within 20 minutes after ingestion.

In the secondary form of RS, or conditioned vomiting, the organic vomiting disorder conditions the patients to expect and experience postprandial vomiting. Gastric emptying is delayed in up to 40% of patients with RS.⁸ As opposed to typical gastroparesis, where vomiting usually occurs 2-6 hours after eating, in conditioned vomiting it occurs within 5-20 minutes. Stress is usually superimposed in this clinical setting of diabetic or idiopathic gastroparesis. The appearance of RS in the background of gastroparesis can be misinterpreted as a failure of treatment of gastroparesis and rumination will persist despite aggressive gastroparesis therapy, including placing a gastric electrical stimulator.

Additionally, in gastroparesis, vomiting is usually preceded by a history of early satiety, nausea, fullness, and inability to finish meals and sometimes dry heaving, aspects that are not present in RS.

In both types of rumination syndrome, there is accompanying heartburn, due to refluxed material contacting the esophageal mucosa during the regurgitation event, and PPIs may be beneficial. Unlike true GERD, there is a lack of nighttime symptoms as there is no food or liquid intake at those times. This timing aspect and lack of nocturnal symptoms is what differentiates RS from gastroesophageal reflux disease.

In the differential diagnosis of RS, one must consider bulimia or anorexia. The history of these disorders includes a long history of struggling with food and weight. Additionally, the onset of vomiting is not readily identified with life events and is not related to the clinical setting of the gastroparesis or diabetic milieu. These patients, usually female, may report they began to vomit in high school and college years. In contrast, RS patients are not usually focused on weight loss and are generally motivated to seek treatment and return to a functional lifestyle.

Laboratory evaluation including a complete blood count, a complete metabolic profile and a thyroid

Table 1. The Rome IV Criteria for Rumination Syndrome¹⁷

Diagnostic Criteria ^a for Rumination Syndrome
Must include all of the following:
<ol style="list-style-type: none"> 1. Persistent or recurrent regurgitation of recently ingested food into the mouth with subsequent spitting or remastication and swallowing 2. Regurgitation is not preceded by retching
^a Criteria fulfilled for the last 3 months with symptom onset at least 6 months before diagnosis.
Supportive remarks:
<ul style="list-style-type: none"> • Effortless regurgitation events are usually not preceded by nausea • Regurgitant contains recognizable food that might have a pleasant taste • The process tends to cease when the regurgitated material becomes acidic

stimulating hormone level can help exclude other etiologies of the patients' presentation. Screening for celiac disease is important in the setting of weight loss. Vitamin B12 and folate levels may also aid in assessing evaluating malnutrition.

Hypokalemia, not usually present in gastroparesis, often suggests the diagnosis of RS. Performing an esophagogastroduodenoscopy (EGD) will exclude peptic ulcers and *H. pylori* in patients with abdominal pain and right upper quadrant ultrasound will evaluate for symptomatic cholelithiasis.

While the diagnosis of rumination syndrome relies on thorough history and physical, invasive testing at a tertiary care facility may assist in eliminating the uncertainty regarding the diagnosis or unwillingness by the patient and/or the family to accept this diagnosis. Recently, high resolution manometry with intragastric pressure and esophageal impedance measurement has been used to confirm that regurgitation from the stomach is ascending towards the mouth (Figure 1). Impedance testing evaluates for regurgitation events associated with increased intragastric pressure coordinated with transient LES relaxations. However, pH testing for reflux is not recommended since acid in the esophagus is the result of rumination, not a cause of the symptoms. If performed, however, a fall in pH to less than 4.0 will be seen briefly postprandially when a rumination

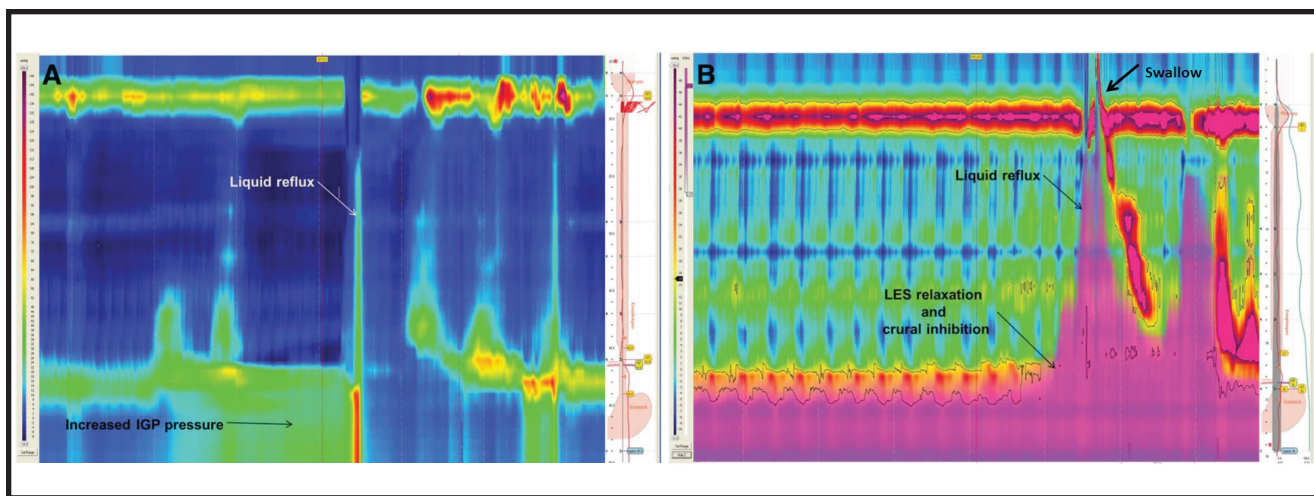


Figure 1. High-resolution impedance manometry demonstrating increased gastric pressure, LES relaxation, and regurgitation of contents from the stomach, orad into the esophagus and mouth (note the relaxation of the upper esophageal sphincter) followed by swallowing of some of the regurgitated material (arrow).¹⁶

event occurs, but no pH changes occur overnight while the patient is fasting. Antroduodenal manometry has traditionally been the final test of choice to diagnose rumination syndrome, but is only available in a few academic settings. This test involves fluoroscopically placing a manometric catheter into the small intestine with ports to measure pressure at the antrum, duodenum and proximal jejunum. A simultaneous increase in pressure at all recording levels following oral intake is a signal that a rumination event with abdominal muscle contraction has occurred and is termed an “R-wave” (Figure 2). It is important to note, however, that this test is not necessary to diagnose RS.

TREATMENT METHODS

A multidisciplinary team consisting of the gastroenterologist, nutritionist and mental health specialist is recommended to manage rumination syndrome. These different approaches address breathing techniques, relaxation, meditation, as well as pharmacologic approaches for inducing improvement and, over time, cessation of rumination.

Relaxation/Meditation Techniques

Initially, the physician needs to establish a rapport and trust with the patient. Patients with rumination syndrome often have undergone many tests and have seen multiple physicians without fully understanding their pathology. Despite negative evaluations and endoscopies, patients continue to experience symptoms leading to frustration. Reassurance and education are key for the patient and

their families. Diagrams explaining the anatomy and physiology of the upper gastrointestinal tract may be utilized; an explanation of the negative results should be included. A conversation regarding the patients’ expectations is paramount.⁹

The mainstay of treatment in RS consists of behavioral therapy focusing on breathing and relaxation techniques. These are more successful when performed by a mental health specialist. Breathing techniques are based on habit reversal and properly creating a competing response to the behaviors of regurgitation thus distracting to reduce the targeted regurgitation events.¹⁰

Breathing techniques begin with diaphragmatic breathing as patients begin a meal. Patients are asked to sit in a relaxed, upright position. The patient then places one hand on the chest and the other hand on the abdomen. The goal is to take slow, deep inspirations by moving only the abdomen without moving the chest.^{11,12} Calm diaphragmatic breathing is performed throughout the meal and at least 3-10 minutes after the meal allowing enough time for food to pass to a more distal area of the stomach.

Combined with diaphragmatic breathing, relaxation techniques play an important role in the treatment of RS. Auditory media for relaxation are commonly available to help the patient intentionally relax.¹²

After successful consumption of small snacks, the patient’s diet should be advanced slowly in a stepwise fashion to more challenging volumes.

These approaches take weeks to months to master

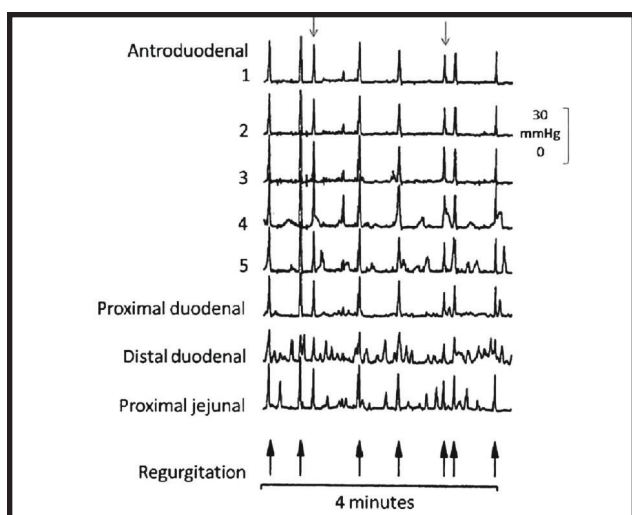


Figure 2. Antroduodenal manometry showing simultaneous increase in pressure across all measurement levels extending from the jejunum to the antrum and esophagus as the regurgitation event develops. These are the “R-waves”.^{11,16}

since the entire eating process requires reprogramming of the gastric response. And while most patients improve their functional level and quality of life occasional relapses can still occur, particularly during periods of stress.

Pharmacologic Therapy

Proton pump inhibitors may be required for protection of the esophageal mucosa. Antiemetic medications such as ondansetron or promethazine are required for breakthrough symptoms. Tricyclic anti-depressants (TCA) play a role in decreasing gastric hypersensitivity, the sensation of fullness and abdominal muscle pain, in addition to decreasing gastric sensitivity.^{13,14} TCAs (e.g. nortriptyline) may be titrated started at 10 mg at bedtime and maybe titrated up to a range of 50 mg to 100 mg at bedtime with caution to avoid somnolence, fatigue or drowsiness. Doxepin may be substituted in the setting of somnolence. Baclofen (10 mg before meals) reduces the number of transient relaxations of the lower esophageal sphincter, thus decreasing the gastric volume being regurgitated. Studies show positive evidence of decreased post-prandial events on high-resolution manometry impedance recordings during Baclofen therapy, which corresponded to decreased symptoms.¹⁵

NUTRITIONAL SUPPORT

Behavioral therapy for rumination syndrome can take weeks to months to achieve its full effect.

Nutritional support prevents the complications including dehydration, vitamin deficiencies and marked hypokalemia which may require frequent hospitalizations. In patients awaiting response to behavioral therapy, a temporary jejunostomy tube provides enteral nutrition while bypassing the stomach. This aggressive approach improves quality of life, allows patients to concentrate on breathing treatments, return to work and overall become more functional. The jejunostomy tube may be placed laparoscopically, endoscopically or by interventional radiology depending on the center. Percutaneous endoscopic gastrostomy with jejunostomy combination is not recommended since oral intake is being encouraged and the presence of a feeding tube in the pylorus limits pyloric diameter and gastric emptying. The benefit of laproscopic placement is the ability to obtain a full thickness biopsy of the gastric wall to assess the status of the gastric smooth muscle, interstitial cells of Cajal and enteric neuronal plexus. This histology will be normal in primary RS but may be abnormal in RS accompanying gastroparesis. Patients need to be motivated to attempt two to three meals per day while practicing the breathing techniques and receiving their jejunostomy tube feeding at night to maintain weight and micronutrients. An increased patient weight prompts decreased nocturnal feeding. As success is achieved, the jejunostomy tube can be clamped and subsequently removed usually within three to six months.

TAKE HOME PEARLS

Rumination syndrome, in our experience at a motility referral center, is the most underdiagnosed and underappreciated etiology of unexplained vomiting and is seen weekly in our practice. The diagnosis is made by a careful history with focus on timing of the post-prandial regurgitation, which is fountain-like and effortless with the regurgitated material being re-swallowed or vomited. At the same time, an effort to identify the precipitating stressful event must be pursued. The focus of treatment is using breathing and relaxation techniques to distract patients as they attempt to eat small meals. A close relationship between the doctor and the patient is paramount in the treatment of this disease and a mental health specialist may be required to maximize the relaxation training as well as address the underlying provocative event. In addition, a pharmacologic approach with a TCA for gastric sensitivity and abdominal pain is important. Physicians

should also recognize the subset of patients in whom a feeding jejunostomy tube is necessary to maintain nutrition and electrolyte balance while the patient masters the breathing and relaxation approaches, slowly increase oral caloric intake and finally overcomes the rumination reflex. ■

References

1. Kanner, L (February 1936), "Historical notes on rumination in man", Medical Life 43 (2): 27–60
2. Brockbank, EM (1907), "MERYCISM OR RUMINATION IN MAN", British Medical Journal 1 (2408): 421–427
3. Rao s, Parkman H, McCallum RW, Cooper, CJ, Sunny J. Handbook of Gastrointestinal Motility and Functional Disorders. 2015: 145-155.
4. Talley NJ. Rumination Syndrome. Gastroenterol Hepatol. 2011;7(2):117-118
5. Tack, Jan; Talley, Nicholas J; Camilleri, Michael; Holtmann, Gerald; Hu, Pinjin; Malagelada, Juan-R; Stanghellini, Vincenzo (2006), "Functional gastroduodenal disorders" (PDF), Gastroenterology 130 (5): 1466–1479, doi:10.1053/j.gastro.2005.11.059
6. Kessing BF, Govaert F, Masclee AAM, et al. Impedance measurements and high-resolution manometry help to better define rumination episodes. Scand J Gastroenterol. 2011;46: 1310–1315.
7. Kessing BF, Bredenoord AJ, Smout AJ. Objective manometric criteria for the rumination syndrome. Am J Gastroenterol. 2014;109(1):52–59.
8. Miller C, Twillman R, Foran P, et al. Gastric emptying results in conditioned vomiting disorder: the concept of a primary entity as well as learned reflex [abstract 281]. J Investig Med 2008;56:436.
9. Tack J, Blondeau K, Boecxstaens V, et al. Review article: the pathophysiology, differential diagnosis and management of rumination syndrome. Aliment Pharmacol Ther. 2011;33: 782–788.
10. Shay SS, Johnson LF, Wong RK, et al. Rumination, heartburn, and daytime gastroesophageal reflux. A case study with mechanisms defined and successfully treated with biofeedback therapy. J Clin Gastroenterol. 1986;8:115–126.
11. Soykan I, Chen J, Kendall BJ, McCallum RW. The rumination syndrome: clinical and manometric profile, therapy, and long-term outcome. Dig Dis Sci. 1997; 42 (9):1866-1872
12. Chitkara DK, Van Tilburg M, Whitehead WE, et al. Teaching diaphragmatic breathing for rumination syndrome. Am J Gastroenterology 2006;101:2449–52.
13. Sawhney MS, Prakash C, Lustman PJ, et al. Tricyclic antidepressants for chronic vomiting in diabetic patients. Dig Dis Sci 2007;52: 418–24.
14. Mertz H, Fass R, Kodner A, et al. Effect of amitriptyline on symptoms, sleep, and visceral perception in patients with functional dyspepsia. Am J Gastroenterol 1998;93:160–5.
15. Blondeau K, Boecxstaens V, Rommel N, et al. Baclofen improves symptoms and reduces postprandial flow events in patients with rumination and supragastric belching. Clin Gastroenterol Hepatol. 2012;10(4):379-384.
16. Hejazi R, McCallum RW. Rumination syndrome: a review of current concepts and treatments. Am J Med Sci. 2014 Oct;348(4):324-9.
17. Stanghellini V, Chan FK, Hasler WL, Malagelada JR, Suzuki H, Tack J, Talley NJ. Gastroduodenal Disorders. Gastroenterology. 2016 May;150(6):1380-92.

PRACTICAL GASTROENTEROLOGY

*Celebrating
Over Four Decades
of Service*

practicalgastro.com