

Richard W. McCallum, MD, FACP, FRACP (Aust), FACG, AGAF

## Review of Esophageal Rings: Diagnosis and Treatments



Majd Michael



Richard W. McCallum

The investigation of solid phase dysphagia often includes utilizing a number of radiographic and endoscopic studies to establish a diagnosis. In addition, esophageal motility testing is required to assess both peristalsis of esophageal smooth muscle and the function of the lower esophageal sphincter. This article describes a patient with long standing dysphagia and reviews the entities of Type “A” and Type “B” esophageal rings as well as treatment and management strategies.

### CASE

**A** 48 year-old male with a past medical history of chronic sinusitis, sleep apnea and hyperlipidemia was referred for non-progressive dysphagia to solid food for the past 16 years. He denied heartburn, abdominal pain, nausea and vomiting. His past surgical history was only significant for sinus surgery. His past social history included a six pack year smoking history and the consumption of alcohol on a social basis but he denied illicit drug use. On presentation, his vital signs and physical exam were unremarkable.

High resolution esophageal manometry documented a normal lower esophageal sphincter pressure with integrated relaxation pressure (IRP) of 14 mmHg

(normal <15 mmHg). Following wet swallows, there were 100% peristaltic sequences and contractions were of normal amplitude. Striated muscle function was assessed as being within normal limits.

Barium esophagram revealed a thin, annular constriction approximately 2 cm proximal to the GE junction resulting in transient delay of passage of the 13 mm tablet (Figure 1, 2). The tablet passed this first constriction and subsequently stagnated in the distal esophagus approximately 1 cm proximal to the esophagogastric junction (proximal margin of a 3 cm hiatal hernia) (Figure 2).

Esophagogastroduodenoscopy (EGD) revealed a 3 cm hiatal hernia with a type B Schatzki’s ring at the proximal most portion of the hernia (Figure 3). A muscular ring, noted approximately 2 cm proximal to the B ring, was consistent with the endoscopic finding of an “A” ring (Figure 4). Directly visualized dilation of both rings was performed utilizing a 20 mm (60 French) through-the-scope balloon (Figure 5) over two 60-second dilating sessions. Mild trauma, mucosal friability and slight bleeding were visualized

---

Majd Michael, M.D.<sup>1</sup> Richard W. McCallum MD, FACP, FRACP, FACG, AGAF,<sup>2</sup>  
<sup>1</sup>Internal Medicine Residency Program, Department of Internal Medicine <sup>2</sup>Department of Internal Medicine, Director, Center for Neurogastroenterology and GI Motility, Texas Tech University, Paul L. Foster School of Medicine El Paso, TX

by endoscopy (Figure 6) upon completion of dilation. Upon follow up at 6 months, he had continued resolution of his dysphagia and biopsies taken at the time of the initial EGD were negative for eosinophilic esophagitis.

## DISCUSSION

When a patient presents with non-progressive dysphagia for some years, the differential diagnosis should include:

### 1. An esophageal motility disorder

Typically, the entities of nutcracker esophagus<sup>2</sup> and jackhammer esophagus, which represent extremely high amplitude peristaltic contractions as well as diffuse esophageal spasm where peristalsis is impaired,<sup>3</sup> should be considered. Patients with those disorders can present with dysphagia selective for solids as well as degrees of chest pain.

### 2. Eosinophilic esophagitis<sup>5</sup>

Patients have intermittent dysphagia to solids often triggered by specific content of the ingested food. This condition is diagnosed by esophageal biopsy.

### 3. Peptic strictures and malignancy

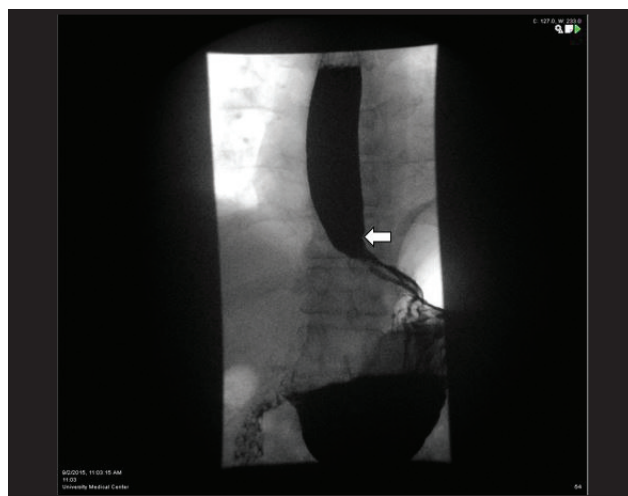
These entities must be considered when solid phase dysphagia progresses into the inability to swallow liquids as well. In the setting of simultaneous onset of both liquid and solid phase dysphagia, achalasia is the classic diagnostic entity.<sup>6</sup>

### 4. Connective tissue disease

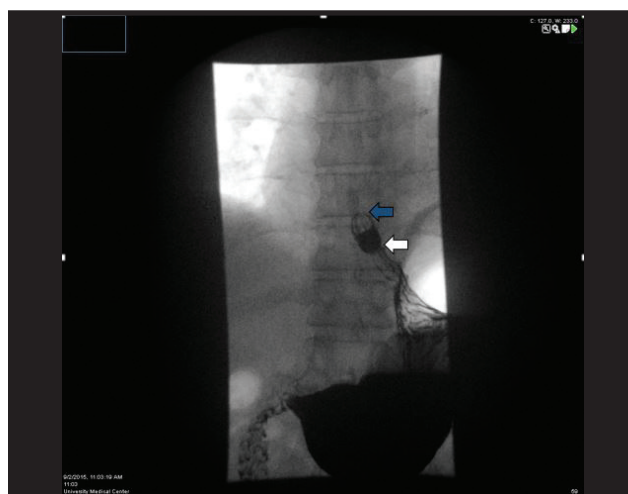
The usual presentation is gastroesophageal reflux disease (GERD) and physical findings of scleroderma in the examination of the hands. In addition, patients may endorse a history of Raynaud's and/or Sjogern's syndrome meeting the criteria for CREST syndrome. As scleroderma advances, the dysphagia may progress to include liquids.<sup>4</sup>

### 5. An esophageal epiphrenic diverticulum

These diverticula are located immediately proximal to the GE junction, can enlarge and, when containing food, can result in



**Figure 1.** Barium study demonstrates “A” ring located approximately 2 cm proximal to the hiatal hernia (see arrow)

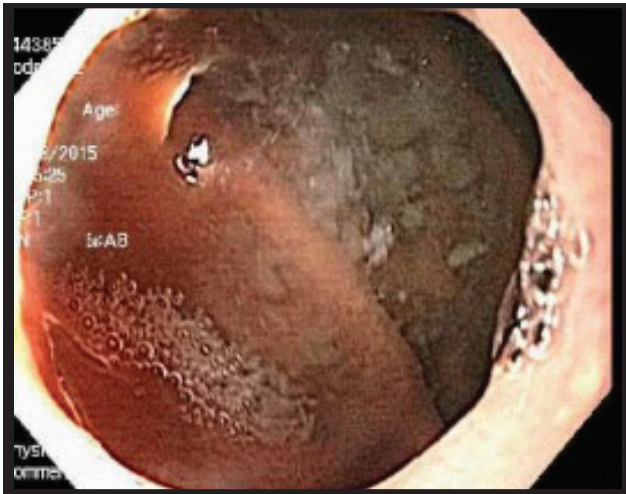


**Figure 2.** The 13 mm tablet lodged at the entry of the hiatal hernia. The white arrow indicates a web-like narrowing representing a mucosal “B” ring. In addition the “A” or muscular ring is noted approximately 2 cm proximally (see blue arrow)

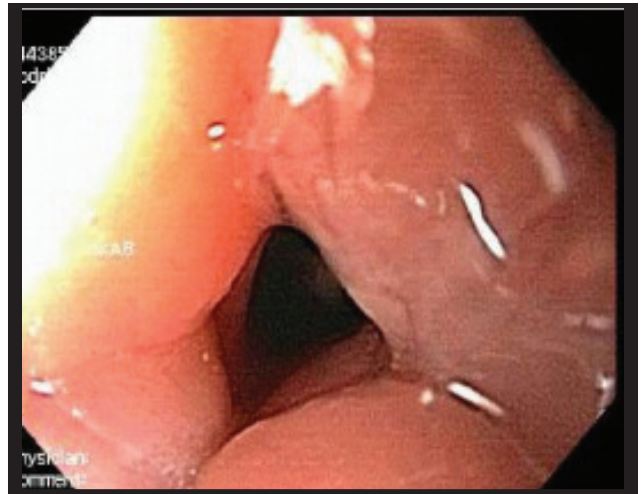
distortion and angulation of the GE junction thus resulting in solid phase dysphagia.

### 6. Dysphagia lusoria<sup>1</sup>

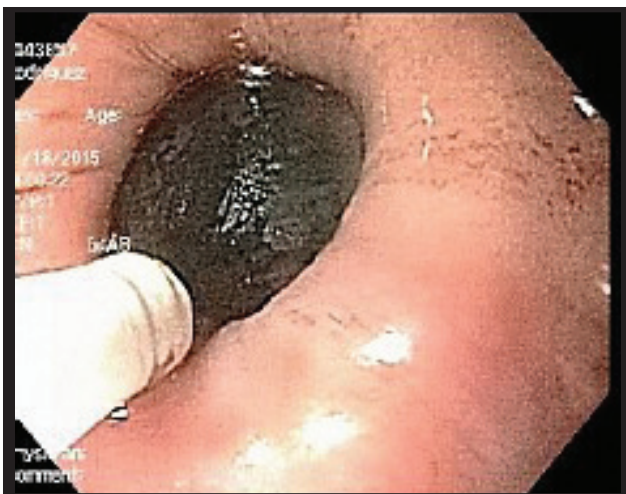An aberrant right subclavian artery arises as the last branch of the aortic arch. This vessel then crosses posteriorly across the esophagus from left to right and results in a compressing effect. Dysphagia can present in childhood or later in life when the vessel develops more atherosclerosis and becomes calcified or hardened.



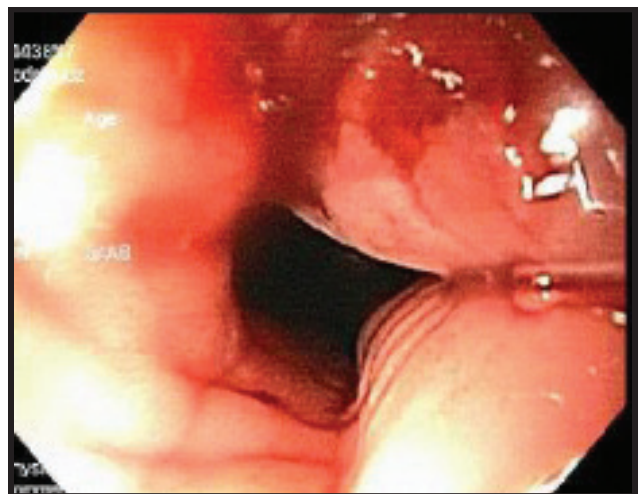
**Figure 3.** Type B ring proximal to the hiatal hernia



**Figure 4.** Type "A" muscular ring



**Figure 5.** Through the endoscope balloon dilation of both rings using a 20 mm (60 F) balloon



**Figure 6.** Post-endoscopic dilation demonstrating trauma and sequelae of the balloon dilation

## 7. Leiomyomas

Submucosal tumors typically located in the distal esophagus, often with close proximity to the GE junction. As these lesions increase in size, they may cause dysphagia and may require resection. Endoscopic ultrasound may be utilized for diagnostic purposes.

## Esophageal Rings

- **A ring** – A muscular ring resulting from the thickening of a segment of normal smooth muscle in the esophagus. It occurs at the tubulovesicular junction located approximately

2- 3 cm proximal to the squamocolumnar junction and is covered totally by squamous epithelium.<sup>2</sup> This is a rare entity. The A ring, usually seen in children, is thought to be present at birth and is regarded as a developmental anomaly.<sup>7</sup> Gastroesophageal reflux disease is not thought to be a factor in the genesis of the esophageal muscular ring.<sup>7</sup>

- **B ring (Schatzki's B ring)** – Termed Schatzki's ring after a Boston radiologist, these rings are located at the squamocolumnar junction, are covered with squamous mucosa proximally and columnar epithelium distally and define the



proximal margin of a hiatal hernia. In contrast to the A ring, these rings are much more prevalent. When the mucosal ring caliber is <13 mm patients nearly always have dysphagia to solids. Patients with a ring diameter of 13-20 mm usually have no dysphagia.<sup>9-10,12</sup> Schatzki's rings are considered the most common cause of dysphagia limited to solids and are always associated with hiatal hernias.

The incidence of Schatzki's ring varies between 4 and 16% of routine barium studies.<sup>13</sup> The incidence increases with age and is rare under the age of 30. The progression from an asymptomatic hiatal hernia to a symptomatic B ring is unclear, but the association with GERD seems to be invariably present.<sup>14</sup> This etiological relationship between the type B mucosal ring and reflux may explain the possibility of recurrence of dysphagia sometime after the initial dilation treatment. Hence there is a role for prophylactic treatment of the suspected GERD.<sup>1</sup>

Schatzki's rings may also present as a food impaction. A single-contrast radiographic study, preferred over a double-contrast, is more effective in demonstrating esophageal rings than endoscopy. A barium swallow alone is not sufficient to establish the diagnosis, thus combining a solid bolus challenge (marshmallow or preferably a 13 mm barium tablet) as an ancillary measure should be utilized. The tablet contrast agent will help establish the diagnosis by provoking a delay in the esophagus resulting in patient symptoms while radiographically identifying the exact location of the ring.

Since the A ring is congenital, the occurrence of both A and B rings in the same patient is rare. In the only report in the literature where the occurrence of both A and B rings has been discussed, the frequency was overestimated as 2%.<sup>8</sup>

Dilations of symptomatic lower esophageal rings are safe and well tolerated. Long-term symptom relief can best be achieved by dilation of the esophagus with a balloon technique. The goal is to abruptly break, disrupt and damage the ring and is best achieved by 60 French (20 mm) balloon inflated under endoscopic visualization, a technique called through-the-scope

(TTS) dilation. Long term resolution of the dysphagia can be accomplished by this treatment. Episodic dysphagia may recur but only 20% of the patients will require repeat dilation with recurrences successfully treated by repeat dilations<sup>15</sup> and GERD treatment. It has been shown that long term acid suppression can prevent recurrence of Schatzki's ring after dilation (7.7% vs 58.3  $p=0.011$ )<sup>16</sup> as well as improve both the ring diameter and the ability to pass the tablet through the esophagus.<sup>17</sup>

In addition to TTS balloon dilation, alternative modalities to treat Schatzki's ring including four quadrant biopsies (mean of 9.6 biopsies in one study), electrosurgical incision, steroid injection and dietary measures have been shown to successfully improve dysphagia.<sup>18</sup> Dilation with Maloney and Savary dilator techniques do not induce "abrupt" break in the actual Schatzki's ring and dilate the esophagus diffusely. Thus, they are not recommended.

Conversely, there are limited studies on the treatment of muscular rings with a few case reports supporting botulinum toxin injection.<sup>7,19,20</sup> Aggressive balloon dilation of a type A ring, as illustrated by our case, will presumably induce long term relief of dysphagia.

### Take Home Points for the Gastroenterologist

Type B Schatzki's ring is the most common cause of dysphagia limited to solids, while Type A muscular rings are very infrequent.

We remind the reader that barium swallow with a 13 mm tablet is the key test for highlighting the anatomy of the esophagus. The addition of a solid challenge a 13 mm Barium tablet will establish the diagnosis while reproducing the dysphagia. This approach is more accurate than endoscopy. ■

### References

1. Levitt B, Richter JE. Dysphagia lusoria: a comprehensive review. *Diseases of the esophagus: official journal of the International Society for Diseases of the Esophagus / ISDE* 2007;20:455-60.
2. Agrawal A, Hila A, Tutuian R, Mainie I, Castell DO. Clinical relevance of the nutcracker esophagus: suggested revision of criteria for diagnosis. *Journal of clinical gastroenterology* 2006;40:504-9.
3. Parkman H, McCallum R, Rao S. *GI Motility Testing: SLACK*; 2011.
4. Lock G, Holstege A, Lang B, Schölmerich J. Gastrointestinal manifestations of progressive systemic sclerosis. *Am J Gastroenterol* 1997;92:763-71.

- Murray IA, Joyce S, Palmer J, Lau M, Schultz M. Incidence and features of eosinophilic esophagitis in dysphagia: a prospective observational study. *Scandinavian journal of gastroenterology* 2016;51:257-62.
- Richter JE. Achalasia - an update. *J Neurogastroenterol Motil* 2010;16:232-42.
- Hirano I, Gilliam J, Goyal RK. Clinical and manometric features of the lower esophageal muscular ring. *The American journal of gastroenterology* 2000;95:43-9.
- Goyal RK, Bauer JL, Spiro HM. The nature and location of lower esophageal ring. *N Engl J Med* 1971;284:1175-80.
- Schatzki R, Gary JE. Dysphagia due to a diaphragm-like localized narrowing in the lower esophagus (lower esophageal ring). *The American journal of roentgenology, radium therapy, and nuclear medicine* 1953;70:911-22.
- Ott DJ, Gelfand DW, Wu WC, Castell DO. Esophagogastric region and its rings. *AJR American journal of roentgenology* 1984;142:281-7.
- Goyal RK, Glancy JJ, Spiro HM. Lower esophageal ring. 2. *The New England journal of medicine* 1970;282:1355-62.
- Goyal RK, Glancy JJ, Spiro HM. Lower esophageal ring. 1. *The New England journal of medicine* 1970;282:1298-305.
- Muller M, Gockel I, Hedwig P, et al. Is the Schatzki ring a unique esophageal entity? *World journal of gastroenterology* 2011;17:2838-43.
- Chen YM, Gelfand DW, Ott DJ, Munitz HA. Natural progression of the lower esophageal mucosal ring. *Gastrointestinal radiology* 1987;12:93-8.
- Eckardt VF, Kanzler G, Willems D. Single dilation of symptomatic Schatzki rings. A prospective evaluation of its effectiveness. *Digestive diseases and sciences* 1992;37:577-82.
- Sgouros SN, Vlachogiannakos J, Karamanolis G, et al. Long-term acid suppressive therapy may prevent the relapse of lower esophageal (Schatzki's) rings: a prospective, randomized, placebo-controlled study. *The American journal of gastroenterology* 2005;100:1929-34.
- Novak SH, Shortleeve MJ, Kantrowitz PA. Effective Treatment of Symptomatic Lower Esophageal (Schatzki) Rings With Acid Suppression Therapy: Confirmed on Barium Esophagography. *AJR American journal of roentgenology* 2015;205:1182-7.
- Gonzalez A, Sullivan MF, Bonder A, Allison HV, Bonis PA, Guelrud M. Obliteration of symptomatic Schatzki rings with jumbo biopsy forceps (with video). *Diseases of the esophagus : official journal of the International Society for Diseases of the Esophagus / ISDE* 2014;27:607-10.
- Varadarajulu S, Noone T. Symptomatic lower esophageal muscular ring: response to botox. *Digestive diseases and sciences* 2003;48:2132-4.
- Perez-Arroyo H, Hunter J, Waring JP. Botulinum toxin injection for an esophageal muscular A-ring. *Gastrointestinal endoscopy* 1997;45:193-5.

## PRACTICAL GASTROENTEROLOGY

*Celebrating  
Over Four Decades  
of Service*

[practicalgastro.com](http://practicalgastro.com)