


Carol Rees Parrish, M.S., R.D., Series Editor

Protein Losing Enteropathy: Diagnosis and Management



Andrew P. Copland



John K. DiBaise

Protein losing enteropathy (PLE) is an uncommon etiology of hypoproteinemia. It is caused by protein loss from compromised gastrointestinal (GI) mucosa as a result of GI mucosal diseases, GI tract infections, as well as from disruptions of venous and lymphatic outflow. The prevalence of PLE is poorly understood given the wide variety of causes of both hypoalbuminemia and PLE, and due to a lack of systematic screening. The evaluation of a potential PLE patient includes a careful assessment for alternative causes of hypoalbuminemia and a measurement of GI tract protein loss. This review provides the clinician with diagnostic criteria, as well as management and nutrition support options.

INTRODUCTION

Protein-losing enteropathy (PLE), sometimes referred to as protein-losing gastroenteropathy, is an unusual cause of hypoproteinemia and is characterized by the shedding of large quantities of protein from the gastrointestinal (GI) mucosa. PLE may result from a wide variety of etiologies and can be both a diagnostic and therapeutic challenge to the practicing gastroenterologist. The clinical presentation of PLE may also be complicated by micronutrient deficiencies related to the underlying etiology of the PLE. In some cases, we have noted significant vitamin deficiencies and deficiency of essential fatty acids complicating

the care of these patients. Through the use of a case illustration, we will explore a practical approach to the evaluation and management of PLE.

In early 2016, a 51 year-old woman presented to the GI clinic upon referral by a hematologist because of the development of progressive hypoalbuminemia (albumin 2.6 g/dL) which had been identified approximately 1 year earlier. She described one normal appearing stool per day, denied any GI complaints, and her physical examination was entirely normal.

PLE is generally considered to be a rare condition; however, given a lack of systematic screening and a wide variety of causes of hypoalbuminemia, its prevalence is poorly understood. There are robust data describing an incidence of up to 18% among survivors of the Fontan procedure, used as treatment of the univentricular congenital heart; however, data are much more limited

(continued on page 24)

Andrew P. Copland, MD¹ John K. DiBaise, MD²
¹Division of Gastroenterology and Hepatology, University of Virginia Health System, Charlottesville, VA ²Division of Gastroenterology and Hepatology, Mayo Clinic in Arizona, Scottsdale, AZ

(continued from page 22)

for other causes of PLE.¹ A 2-3% prevalence of PLE has been reported among Asian patients with systemic lupus erythematosus (SLE).² In a study of 24 patients with ileal Crohn’s disease in clinical remission, all had laboratory evidence of PLE (although none had clinical signs), suggesting that the prevalence of PLE may be significantly underrecognized.³ Similarly, in a study from 1975, 22% of 55 patients with primary lymphedema who were screened for PLE were found to have evidence of protein wasting from the GI tract.⁴

Despite the poor understanding of its prevalence, PLE should be a consideration in the evaluation of patients who present with moderate to severe hypoalbuminemia (serum albumin <3.0 g/dL), particularly those who present with edema. Although some patients with PLE present with severe GI symptoms such as diarrhea, which can take on a secretory character, it is important to recognize that not all patients suffering from PLE will exhibit overt GI symptoms. In fact, the key clinical characteristic of PLE is symptomatic hypoalbuminemia which manifests most commonly as edema. Other clinical manifestations generally reflect the underlying disease responsible for PLE.

Pathophysiology

The protein loss in the bowel typically results in serum albumin levels <3.0 g/dL, and frequently <2.0 g/dL. In the normal GI tract, only 1-2% of total daily protein is lost through active intestinal secretions and mucosal turnover.⁵ This is significantly different from the dramatic protein losses from the GI tract seen in PLE, which can result in daily loss of as much as 60% of the total serum protein. ⁶ Because albumin contributes about 80% of the total colloidal osmotic effect of human serum due to its oncotic effect and affinity for sodium ions, loss of serum albumin results in third-spacing of fluid and generally manifests clinically as peripheral edema, ascites, and pleural effusions.⁷ In addition to symptomatic hypoalbuminemia, patients presenting with PLE may be at increased risk of infection and thrombosis due to concomitant stool loss of serum immunoglobulins and key anticoagulant proteins respectively, although neither occurs commonly.

In the context of increased serum protein loss, the body will attempt to compensate by increasing protein synthesis. As such, serum levels of rapid turnover proteins including prealbumin, immunoglobulin E (IgE), and insulin may remain normal.⁸ In contrast,

Table 1. Causes of Hypoalbuminemia Other Than PLE

◆ Impaired Synthesis <ul style="list-style-type: none"> ○ Chronic liver disease
◆ Increased Loss <ul style="list-style-type: none"> ○ Nephrotic syndrome
◆ Dilution <ul style="list-style-type: none"> ○ Volume overload in context of heart failure
◆ Inflammation <ul style="list-style-type: none"> ○ Acute inflammatory response (negative phase reactant) ○ Chronic inflammatory response

insufficient compensatory protein production and low serum level is more often seen with slower turnover proteins such as albumin, ceruloplasmin, fibrinogen, transferrin, and immunoglobulins (other than IgE), as the body has a less robust capacity to increase daily production.⁵ Albumin in particular is a slow turnover protein with a half-life of about 25 days; there is also evidence that the liver is unable to fully compensate for sustained albumin losses.⁷ Decreased serum levels of lipids and trace elements have also been reported in PLE, as has the presence of lymphopenia, particularly in the setting of lymphatic obstruction or malnutrition. The reduction of serum proteins other than albumin seldom causes clinically significant problems.

Her past medical history was notable for remote peptic ulcer disease, hyperlipidemia, seasonal allergies and persistent unexplained peripheral eosinophilia first discovered in 2010. In 1989, she underwent a vagotomy and pyloroplasty for gastric outlet obstruction due to peptic ulcer disease. Extensive evaluations of the eosinophilia by specialists in infectious diseases, hematology, allergy, immunology, and rheumatology were unsuccessful in identifying an etiology.

Alternative causes of hypoalbuminemia

Other causes of hypoalbuminemia are diverse and warrant careful thought when evaluating the hypoalbuminemic patient. In particular, fluid overload (e.g., congestive heart failure), reduced protein synthesis (e.g., chronic liver disease), and other sources of serum protein losses (e.g., nephrotic syndrome) are important

to consider. This evaluation should include a careful history and physical examination, as well as standard evaluations of other causes of hypoalbuminemia noted in Table 1.

A diagnostic evaluation revealed no evidence of chronic liver disease, nephrotic syndrome or congestive heart failure. Alpha-1-antritypsin clearance was found to be 341 mL/24 hours (normal, < 27 mL/24 hr), consistent with PLE.

Testing to Confirm a Diagnosis of PLE

The primary diagnostic test for PLE is stool testing for the presence of alpha-1-antritypsin (A1AT) (Table 2). A1AT is a protein that suffers minimal degradation or active secretion in the GI tract and is of similar molecular weight as albumin. By measuring A1AT levels in both serum and a 24-hour stool collection, A1AT clearance can be calculated as follows:

$$A1AT \text{ clearance} = [(mL \text{ Stool}) \times (\text{stool A1AT mg/dL})] / [\text{serum A1AT mg/dL}]$$

An elevated A1AT clearance >27 mL/day reflects a general state of GI protein loss and has a sensitivity of approximately 80%.⁷ Diarrhea from any cause, however, results in some obligate A1AT loss and, thus, a higher threshold (>56 mL/day) may be required for the diagnosis of PLE in this situation.^{9,10} A1AT is also sensitive to degradation by acid so, in the setting of a hypersecretory state, this test is optimally performed while the patient is receiving acid suppression.¹¹ Finally, A1AT testing of a spot stool specimen may also show elevated levels in PLE, but this is a less sensitive approach and is not recommended in the initial diagnosis.¹⁰ Use of a random stool A1AT level coupled with serum A1AT level, however, may serve as a convenient surveillance method for patients with known PLE undergoing treatment or in remission.

There are a number of other methods to search for protein loss in the GI tract, albeit none as widely available or as safe as the A1AT clearance. Historically, the gold standard test for PLE has been the fecal excretion of ⁵¹Cr labelled albumin, which requires collection of stool for a minimum of 4 days.⁷ It is not only challenging for patients to complete a 4-day stool collection but it exposes them to radiation and it is not widely available. The ⁵¹Cr-albumin clearance may be useful when there is a high clinical suspicion in the context of a negative A1AT clearance given its higher sensitivity. An alternative is technetium 99m-labelled human serum albumin (HSA) scintigraphy. This test

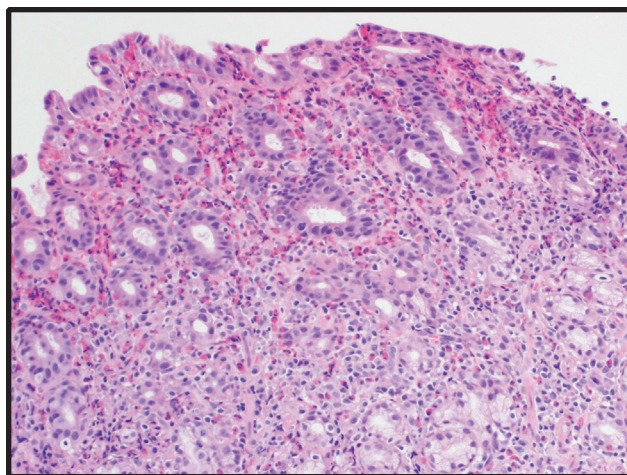


Figure 1.

has demonstrated superior sensitivity and negative predictive value compared to A1AT clearance for the diagnosis of PLE and has the added benefit of not requiring a prolonged stool collection.¹² These tests may also be used to monitor response to treatment.

Upper endoscopy was subsequently performed and was notable for patchy gastric erythema with an atrophic appearance to the stomach. Biopsies from the second portion of the duodenum demonstrated patchy eosinophilia while biopsies from the duodenal bulb were normal. Random biopsies from the stomach showed marked eosinophilia without other abnormalities (Figure 1). Based on the peripheral eosinophilia and presence of eosinophils on the biopsy, the patient was suspected to have eosinophilic gastroenteritis. Interestingly, in 2010, she had undergone upper endoscopy and colonoscopy to evaluate iron deficiency anemia. While both examinations were grossly normal, random biopsies from the stomach revealed a similar intense eosinophilic inflammatory infiltrate throughout the mucosa and submucosa. Biopsies from the duodenum, terminal ileum and colon were normal.

Evaluating Confirmed PLE

When a diagnosis of PLE has been determined, additional testing is necessary in order to identify the underlying cause and help direct treatment. PLE is associated with a diverse set of diseases often affecting multiple organ systems and can be divided into GI and non-GI causes (Table 3). GI sources can be further divided into erosive and nonerosive diseases of the bowel that result in protein loss across the mucosal membrane of the intestine and are detailed in Table 3.

(continued on page 31)

(continued from page 25)

Circulatory dysfunction from cardiac pathology such as congestive heart failure (CHF), constrictive pericarditis, and congenital heart disease can lead to PLE. The most common cardiac cause of PLE occurs in adults with congenital heart disease, a functional single ventricle, treated as a child with a palliative Fontan operation.¹ Post-Fontan patients make up the largest cohort of patients with PLE described in the literature.

PLE is associated with a significant morbidity and mortality depending upon the underlying cause. The five-year mortality after diagnosis of PLE in the setting of a Fontan procedure approaches 50%; however, recent data suggest that advances in our understanding of the disease may have improved this rather dismal outlook.¹³ While data on morbidity and mortality associated with PLE related to other causes are more limited, malnutrition, volume overload, thrombophilia, and secondary immunodeficiency, likely have a significant impact on long-term outcomes.

Because the management of PLE is closely tied to treating the underlying disease, when PLE is identified, a thorough evaluation should be undertaken to better characterize the state of the GI tract mucosa, lymphatic system, and cardiovascular system. This is best approached through upper and lower GI endoscopy with mucosal biopsies as well as infectious studies (focusing on chronic intestinal infections). If conventional endoscopy does not yield a diagnosis, video capsule endoscopy or small bowel enteroscopy have been shown to be useful in patients with known PLE.¹⁴ Cross-sectional imaging of the abdomen and pelvis, echocardiogram, lymphatic/hematologic tests and, sometimes, diagnostic laparoscopy may also be useful depending on the clinical presentation.

Mechanisms Causing PLE

As our understanding of PLE has improved, it has become increasingly clear that a common link between the various etiologies of the disease involves injury to, or breakdown of, the GI epithelium causing increased permeability. Conceptually, this pathology is clear when considering PLE caused by mucosal diseases such as inflammatory bowel disease, eosinophilic gastroenteritis, and microscopic colitis, for example. Poor lymphatic drainage from congenital defects or from significant lymphatic obstruction may cause loss of lymphatic fluid into the GI tract through direct hydrostatic forces.¹⁵ Although the mechanism

responsible for PLE in systemic autoimmune disease is unclear, it has been hypothesized that it results from mucosal or capillary inflammation caused by:

1. local vascular injury mediated by complement or vasculitis
2. lymphatic damage through mesenteric inflammation, or
3. increased endothelial permeability through the effect of inflammatory cytokines.¹⁶

The cause of PLE associated with cardiovascular diseases such as CHF and the Fontan procedure is generally considered to be increased hydrostatic pressure from venous hypertension which, at least in part, results in loss of protein into the GI tract.¹ Interestingly, these patients do not have significantly elevated venous hypertension relative to similar patients without PLE making the exact pathophysiologic process less clear.¹ Some of these patients seem to respond to treatments based at the level of the mucosal membrane, implying that perhaps mucosal injury is again a primary root cause. Some hypothesize that hemodynamic changes associated with the Fontan procedure result in increased mesenteric vascular resistance as a compensatory mechanism to poor cardiac output.¹⁷ This may in turn damage the mucosal epithelium, increase permeability and engorge intestinal lymphatics with an appearance histologically similar to congenital intestinal lymphangiectasia. There are also data to suggest that patients with univentricular-type congenital heart disease may have increased protein loss in the GI tract prior to the Fontan procedure; this may reflect either a response to the initial circulatory dysfunction of the congenital heart disease or concurrent congenital malformation of some component of the GI tract itself.¹⁸ Others have attempted to strengthen the argument for mucosal injury by demonstrating that patients who have undergone a Fontan procedure typically have elevated inflammatory markers.¹⁹

The patient was placed on prednisone for suspected eosinophilic gastroenteritis with rapid normalization of her serum albumin and eosinophils and more gradual normalization of the AIAT clearance. With weaning of the prednisone, an increase in peripheral eosinophils and decrease in albumin occurred prompting initiation of oral cromolyn and budesonide. Thereafter, she was able to eliminate prednisone use. Repeat upper endoscopy approximately one year later was normal

including duodenal and gastric biopsies. Interestingly, biopsies from the upper esophagus demonstrated marked eosinophilia consistent with eosinophilic esophagitis. Notably, she denied dysphagia or any other esophageal symptoms.

Management of PLE

Because PLE is a rare disease with a variety of seemingly disparate causes, there are limited data on its optimal treatment. As such, no single treatment reliably improves PLE in all patients. A core principle is to treat the underlying disease which, if successful, should generally result in improvement in the PLE. Fortunately, most causes of PLE can be readily diagnosed and treated. Examples might include optimization of the management of eosinophilic gastroenteritis as demonstrated in our case illustration, or fenestration of the Fontan heart to improve cardiac output.²⁰

A number of PLE-specific strategies have been described and include dietary, pharmacological or surgical interventions. No controlled studies, however, have been performed to demonstrate the utility of these approaches. It is also important to recognize that there is often a substantial delay in clinical response to treatment of PLE, which may take months to display a measurable response. Nutritional strategies focusing on protein deficiency are important. A high protein

diet is recommended in patients with PLE and may require significantly greater protein intake (2.0-3.0 g/kg/day) than normal (0.6-0.8 g/kg/day) to remain in a positive nitrogen balance.⁶ In patients with associated fat malabsorption, primary or secondary intestinal lymphangiectasia or other lymphatic disorders causing PLE, a lowering of fat intake may decrease pressure on the lymphatics and limit protein leakage.¹⁵ To replace these lost fats, medium-chain triglycerides can be tried as these provide a source of energy rich fats and are absorbed largely via the portal vein rather than the lymphatics.¹⁵ However if a very low fat diet is used > 3 weeks, a source of essential fatty acids will be necessary and fat soluble vitamins may need to be monitored.²¹ If oral intake is inadequate, enteral feedings should be considered. If fat malabsorption has been demonstrated based on a quantitative fecal fat collection with fat ingested or infused enterally, then a semi-elemental or elemental product should be used. If the patient fails enteral, then parenteral will be necessary.

Although dietary modification may not produce obvious benefit in terms of symptoms or degree of protein wasting, the optimization of the PLE patient's nutritional status is important to the success of other therapies and the patient's overall outcome.

Direct replacement of serum albumin by infusion is not a useful long-term strategy as it provides only

Table 2. Testing in PLE

- ◆ Test of Choice: A1AT clearance
 - >27 mL/day reflects a general state of GI protein loss ~ 80% sensitive
 - Diarrhea results in obligate A1AT loss, use a higher threshold (>56 mL/day)
 - A1AT is sensitive to acid degradation; use acid suppression in hypersecretory state
 - Spot A1AT testing of stool specimen is less sensitive and not recommended for diagnosis
 - A random stool A1AT level with serum A1AT level may be a convenient surveillance method for known PLE patients under treatment or in remission
- ◆ Alternatives to A1AT clearance:
 - May be useful when there is a high clinical suspicion in the context of a negative A1AT clearance given its higher sensitivity
 - Technetium 99m-labelled human serum albumin (HSA) scintigraphy
 - Involves radiation
 - No prolonged stool collection
 - ⁵¹Cr-albumin clearance
 - Involves radiation
 - Requires collection of stool for a minimum of 4 days

Table 3. Etiologies of PLE

Erosive Gastrointestinal Disease
<ul style="list-style-type: none"> • Inflammatory bowel disease – primarily Crohn’s ²³ • NSAID enteropathy ¹⁴ • Gut malignancies • Graft vs Host disease • Sarcoidosis ²⁴ • Ulcerative jejunoileitis
Nonerosive Gastrointestinal Disease
<ul style="list-style-type: none"> • Collagenous Colitis ²⁵ • Amyloidosis ²⁶ • Menetrier’s ²⁷ • Gastric Polyposis ²⁸ • Celiac sprue • Tropical Sprue • Eosinophilic gastroenteritis ²⁹ • Lymphocytic gastritis • Bacterial infections (small bowel bacterial overgrowth, strongyloides, ¹⁴ tuberculosis, Helicobacter pylori, ³⁰ Whipple’s disease ³¹) • CMV with hypertrophic gastropathy ³² • Lupus & ANCA (+) vasculitis ¹⁶ • Connective tissue disorders (e.g., Sjogren’s syndrome) • Congenital metabolic abnormalities (e.g., Gaucher’s ³³)
Lymphatic Congestion/Obstruction
<ul style="list-style-type: none"> • Primary lymphangiectasia ³⁴ • Secondary lymphangiectasia (heart failure, mesenteric panniculitis, retroperitoneal fibrosis, tuberculous infiltration, lymphoma, neoplastic lymphoid invasion) ^{15,35,36} • Thoracic duct obstruction • Portal hypertension • Congenital malformation of the lymphatics
Cardiac Disease
<ul style="list-style-type: none"> • Congenital heart disease • Fontan operation for univentricular heart • Congestive heart failure (particularly right heart failure) • Constrictive pericarditis

Table 4. Reported Treatments for PLE

Therapy		
Diuretics	<ul style="list-style-type: none"> • Considered unhelpful with managing the anasarca • May be considered in those with cardiac causes 	
High-dose Spironolactone	<ul style="list-style-type: none"> • Hypothesized to have an effect on the physiology of PLE beyond simply acting as a diuretic, perhaps through similar pleiotropic mechanisms that bring about its benefit in CHF and cirrhosis 	37
Heparin	<ul style="list-style-type: none"> • May stabilize capillary or mucosal endothelium • Retrospective review of 17 patients suggesting improved symptoms but not objective outcomes 	38,39
Corticosteroids	<ul style="list-style-type: none"> • Case reported data in Fontan-associated PLE suggesting benefit 	40
Budesonide	<ul style="list-style-type: none"> • 4 small cases series (total 31 patients w/ PLE after Fontan) suggesting clinical and biochemical improvement with 9mg/day dosing 	19,41-43
Octreotide	<ul style="list-style-type: none"> • Case reported in treatment for PLE from a variety of causes • May favorably modify intestinal blood or lymphatic flow and decrease vascular permeability through modulation of vasoactive peptides 	13,26,44,45
Cetuximab*	<ul style="list-style-type: none"> • Case reported in treatment for PLE associated with Ménétrier's 	46
Everolimus**	<ul style="list-style-type: none"> • Case reported in treatment for PLE associated with primary intestinal lymphangiectasia 	47

* *Epidermal growth factor receptor monoclonal antibody*

***mTOR kinase Inhibitor*

short-term benefit, is expensive, and does not reverse the underlying pathophysiology. In the acute setting, albumin infusion may help patients suffering from severe third-spacing of fluid due to marked hypoalbuminemia as a bridge to more durable therapies.²²

Supportive measures to avoid complications resulting from fluid retention contribute meaningfully to PLE patients' quality of life. Use of compression stockings may help decrease edema and improve functional status. Careful skin care along with edema management is important to avoid pressure ulcerations and other complications of skin breakdown.

Although there are a number of anecdotal case reports and small case series of medical therapies for

patients with specific causes of PLE, there are no high quality randomized controlled trials of any therapy in PLE (see Table 4). In some cases, a surgical approach to the primary underlying GI pathology is necessary. In inflammatory bowel disease, for example, this might result in resection of active bowel affected. Gastrectomy may prove curative for patients with Ménétrier's disease.

Practical approach to PLE

Given the rarity of the PLE and the lack of rigorous supportive data, the treatment of PLE can be a puzzle to the clinician. The initial step in the evaluation of

(continued on page 36)

(continued from page 34)

hypoalbuminemia is to exclude other, more common, causes such as liver and renal diseases. When concern over PLE remains, the A1AT clearance test is recommended as the test of choice given its reliability, relative inexpense, and wide availability. After a diagnosis of PLE has been made, the following approach is suggested:

1. Aggressive pursuit to identify the underlying disease responsible for PLE and treat accordingly while encouraging a high protein diet and supportive measures for fluid retention when present. A low-fat diet and supplementation with medium chain triglyceride supplementation should be considered on an individual basis. Monitoring and treatment of any associated malnutrition and/or micronutrient deficiencies, when present, is also important. In certain conditions where severe symptoms prevent adequate oral intake, occasional use of either enteral or parenteral support may be needed.
2. If cardiac disease is an underlying etiology, addition of diuretic regimen including spironolactone should be considered. The chronic use of diuretics in other settings, while commonly attempted, is otherwise generally discouraged as is the long-term use of intermittent albumin infusions. The use of other “heart failure” medications in order to optimize cardiac output in those with cardiac etiologies of PLE may also be pursued.
3. A trial of pharmacological agents such as corticosteroids, heparin, and octreotide may be considered in patients who have not responded to other measures, but should not be considered primary therapeutic agents for PLE. The use of cetuximab and everolimus should be considered based upon its reported use in relevant underlying diseases. If a trial of budesonide 9mg daily results in clinical improvement, a gradual taper over several months is recommended, recognizing that recurrence is common after discontinuation. Subcutaneous heparin or octreotide may be used in combination with oral or intravenous corticosteroids.

4. Periodic monitoring of the degree of PLE is advised, for example, by using A1AT clearance, after treatment is initiated. Similarly, periodically monitoring the serum albumin level is recommended with the assessment of other serum chemistries and micronutrients on a case-by-case basis.

CONCLUSION

The patient described in our case illustration represents a typical case of PLE with a GI etiology with the exception of an absence of edema. It highlights the need to recognize PLE as a cause of unexplained hypoalbuminemia even in the absence of GI symptoms or evidence of fluid retention. PLE can occur in the context of a myriad of diseases ranging from primary GI mucosal disorders, to malignancies, to lymphatic disorders, to congenital heart disease. Diagnosis is most commonly confirmed by the A1AT clearance test. The care of the patient with PLE can be challenging and often requires a multidisciplinary approach. While the evidence regarding the management of PLE is limited, treatment primarily focuses of the underlying disease with the addition of supportive measures to manage complications such as edema. ■

References

1. Rychik J. Protein-losing enteropathy after Fontan operation. *Congenital heart disease*. 2007;2(5):288-300.
2. Chng HH et al. Major gastrointestinal manifestations in lupus patients in Asia: lupus enteritis, intestinal pseudo-obstruction, and protein-losing gastroenteropathy. *Lupus*. 2010;19(12):1404-1413.
3. Biancone L, Fantini M, Tosti C, et al. Fecal alpha 1-antitrypsin clearance as a marker of clinical relapse in patients with Crohn's disease of the distal ileum. *Eur J Gastroenterol Hepatol*. 2003;15(3):261-266.
4. Eustace PW, Gaunt JI, Croft DN. Incidence of protein-losing enteropathy in primary lymphoedema using chromium-51 chloride technique. *Br Med J*. 1975;4(5999):737.
5. Schmidt PN, Blirup-Jensen S, Svendsen PJ, et al. Characterization and quantification of plasma proteins excreted in faeces from healthy humans. *Scand J Clin Lab Invest*. 1995;55(1):35-45.
6. Umar SB, DiBaise JK. Protein-losing enteropathy: case illustrations and clinical review. *Am J Gastroenterol*. 2010;105(1):43-49; quiz 50.
7. Levitt DG, Levitt MD. Human serum albumin homeostasis: a new look at the roles of synthesis, catabolism, renal and gastrointestinal excretion, and the clinical value of serum albumin measurements. *Int J Gen Med*. 2016;9:229-255.
8. Takeda H, Ishihama K, Fukui T, et al. Significance of rapid turnover proteins in protein-losing gastroenteropathy. *Hepatogastroenterology*. 2003;50(54):1963-1965.

9. Udink Ten Cate FE, Hannes T, Germund I, et al. Towards a proposal for a universal diagnostic definition of protein-losing enteropathy in Fontan patients: a systematic review. *Heart (British Cardiac Society)*. 2016;102(14):1115-1119.
10. Strygler B, Nicar MJ, Santangelo WC, et al. Alpha 1-antitrypsin excretion in stool in normal subjects and in patients with gastrointestinal disorders. *Gastroenterology*. 1990;99(5):1380-1387.
11. Takeda H, Nishise S, Furukawa M, et al. Fecal clearance of alpha1-antitrypsin with lansoprazole can detect protein-losing gastropathy. *Digestive diseases and sciences*. 1999;44(11):2313-2318.
12. Chau TN, Mok MY, Chan EY, et al. Evaluation of performance of measurement of faecal alpha(1)-antitrypsin clearance and technetium-99m human serum albumin scintigraphy in protein-losing enteropathy. *Digestion*. 2011;84(3):199-206.
13. John AS, Johnson JA, Khan M, et al. Clinical outcomes and improved survival in patients with protein-losing enteropathy after the Fontan operation. *J Am Coll Cardiol*. 2014;64(1):54-62.
14. Takenaka H, Ohmiya N, Hirooka Y, et al. Endoscopic and imaging findings in protein-losing enteropathy. *J Clin Gastroenterol*. 2012;46(7):575-580.
15. Tift WL, Lloyd JK. Intestinal lymphangiectasia. Long-term results with MCT diet. *Arch Dis Child*. 1975;50(4):269-276.
16. Law ST, Ma KM, Li KK. Protein-losing enteropathy associated with or without systemic autoimmune disease: what are the differences? *Eur J Gastroenterol Hepatol*. 2012;24(3):294-302.
17. Ostrow AM, Freeze H, Rychik J. Protein-losing enteropathy after fontan operation: investigations into possible pathophysiologic mechanisms. *Ann Thorac Surg*. 2006;82(2):695-700.
18. Patel JK, Loomes KM, Goldberg DJ, et al. Early Impact of Fontan Operation on Enteric Protein Loss. *Ann Thorac Surg*. 2016;101(3):1025-1030.
19. Thacker D, Patel A, Dodds K, et al. Use of oral budesonide in the management of protein-losing enteropathy after the Fontan operation. *Ann Thorac Surg*. 2010;89(3):837-842.
20. Jacobs ML, Rychik J, Byrum CJ, et al. Protein-losing enteropathy after Fontan operation: resolution after baffle fenestration. *Ann Thorac Surg*. 1996;61(1):206-208.
21. Shah ND LB. The Use of Medium-Chain Triglycerides in Gastrointestinal Disorders. *Practical Gastroenterology*. 2017. [In Press]
22. Rychik J, Spray TL. Strategies to treat protein-losing enteropathy. *Semin Thorac Cardiovasc Surg Pediatr Card Surg Annu*. 2002;5:3-11.
23. Baert D, Wulfrank D, Burvenich P, et al. Lymph loss in the bowel and severe nutritional disturbances in Crohn's disease. *J Clin Gastroenterol*. 1999;29(3):277-279.
24. Popovic OS, Brkic S, Bojic P, et al. Sarcoidosis and protein losing enteropathy. *Gastroenterology*. 1980;78(1):119-125.
25. Nakaya Y, Hosokawa SK, Kataoka Y, et al. Collagenous Colitis Associated with Protein-losing Enteropathy. *Intern Med*. 2015;54(22):2959-2960.
26. Fushimi T, Takahashi Y, Kashima Y, et al. Severe protein losing enteropathy with intractable diarrhea due to systemic AA amyloidosis, successfully treated with corticosteroid and octreotide. *Amyloid*. 2005;12(1):48-53.
27. Meuwissen SG, Ridwan BU, Hasper HJ, et al. Hypertrophic protein-losing gastropathy. A retrospective analysis of 40 cases in The Netherlands. The Dutch Menetrier Study Group. *Scand J Gastroenterol Suppl*. 1992;194:1-7.
28. Yamashita K, Saito M, Itoh M, et al. Juvenile polyposis complicated with protein losing gastropathy. *Intern Med*. 2009;48(5):335-338.
29. Siewert E, Lammert F, Koppitz P, et al. Eosinophilic gastroenteritis with severe protein-losing enteropathy: successful treatment with budesonide. *Dig Liver Dis*. 2006;38(1):55-59.
30. Cohen HA, Shapiro RP, Frydman M, et al. Childhood protein-losing enteropathy associated with Helicobacter pylori infection. *J Pediatr Gastroenterol Nutr*. 1991;13(2):201-203.
31. Freeman HJ. Tropheryma whipplei infection. *World J Gastroenterol*. 2009;15(17):2078-2080.
32. Megged O, Schlesinger Y. Cytomegalovirus-associated protein-losing gastropathy in childhood. *Eur J Pediatr*. 2008;167(11):1217-1220.
33. Mhanni AA, Kozenko M, Hartley JN, et al. Successful therapy for protein-losing enteropathy caused by chronic neuronopathic Gaucher disease. *Mol Genet Metab Rep*. 2016;6:13-15.
34. Vignes S, Bellanger J. Primary intestinal lymphangiectasia (Waldmann's disease). *Orphanet J Rare Dis*. 2008;3:5.
35. Tsukamoto A, Nakamura F, Nannya Y, et al. MALT lymphoma of the small bowel with protein-losing enteropathy. *Int J Hematol*. 2014;99(2):198-201.
36. Pratz KW, Dingli D, Smyrk TC, et al. Intestinal lymphangiectasia with protein-losing enteropathy in Waldenstrom macroglobulinemia. *Medicine (Baltimore)*. 2007;86(4):210-214.
37. Ringel RE, Peddy SB. Effect of high-dose spironolactone on protein-losing enteropathy in patients with Fontan palliation of complex congenital heart disease. *Am J Cardiol*. 2003;91(8):1031-1032, A1039.
38. Donnelly JP, Rosenthal A, Castle VP, et al. Reversal of protein-losing enteropathy with heparin therapy in three patients with univentricular hearts and Fontan palliation. *J Pediatr*. 1997;130(3):474-478.
39. Ryerson L, Goldberg C, Rosenthal A, et al. Usefulness of heparin therapy in protein-losing enteropathy associated with single ventricle palliation. *Am J Cardiol*. 2008;101(2):248-251.
40. Rychik J, Piccoli DA, Barber G. Usefulness of corticosteroid therapy for protein-losing enteropathy after the Fontan procedure. *Am J Cardiol*. 1991;68(8):819-821.
41. Turner Z, Lanford L, Webber S. Oral budesonide as a therapy for protein-losing enteropathy in patients having undergone Fontan palliation. *Congenital heart disease*. 2012;7(1):24-30.
42. Gursu HA, Erdogan I, Varan B, et al. Oral budesonide as a therapy for protein-losing enteropathy in children after the Fontan operation. *J Card Surg*. 2014;29(5):712-716.
43. Schumacher KR, Cools M, Goldstein BH, et al. Oral budesonide treatment for protein-losing enteropathy in Fontan-palliated patients. *Pediatr Cardiol*. 2011;32(7):966-971.
44. Filik L, Oguz P, Koksak A, et al. A case with intestinal lymphangiectasia successfully treated with slow-release octreotide. *Dig Liver Dis*. 2004;36(10):687-690.
45. Rothenberg M, Pai R, Stuart K. Successful use of octreotide to treat Menetrier's disease: a rare cause of abdominal pain, weight loss, edema, and hypoalbuminemia. *Digestive diseases and sciences*. 2009;54(7):1403-1407.
46. Settle SH, Washington K, Lind C, et al. Chronic treatment of Menetrier's disease with Erbitux: clinical efficacy and insight into pathophysiology. *Clin Gastroenterol Hepatol*. 2005;3(7):654-659.
47. Ozeki M, Hori T, Kanda K, et al. Everolimus for Primary Intestinal Lymphangiectasia With Protein-Losing Enteropathy. *Pediatrics*. 2016;137(3):e20152562.