

Carol Rees Parrish, M.S., R.D., Series Editor

Lactic Acidosis: A Lesser Known Side Effect of Thiamine Deficiency



Kelly O'Donnell

Elevated lactate levels are a common occurrence in the critically ill patient. There are a variety of causes, including tissue hypoperfusion, infection and liver dysfunction. A lesser known cause is thiamine deficiency. Thiamine is a water soluble vitamin essential for carbohydrate metabolism. Given limited stores along with daily requirements, thiamine deficiency may occur quickly in patients presenting with persistent vomiting, malnutrition and alcoholism. The purpose of this paper is to help identify those patients at risk for thiamine deficiency and recognize signs and symptoms of deficiency including, but not limited to, elevated lactate levels.

INTRODUCTION

Lactate, produced by most tissues in the body, is an end product of anaerobic metabolism. Reasons for elevated lactate levels include, sepsis, shock or tissue hypoperfusion, ischemic bowel, uncontrolled source of infection, liver dysfunction, medications and thiamine deficiency, to name a few. Lactate is often used as a marker of illness severity with elevated levels associated with adverse outcomes and mortality as high as 80%.¹

Thiamine is a water-soluble vitamin with limited tissue storage. When oral intake is reduced, stores may be consumed in as quickly as 18-20 days.² Thiamine is a cofactor for pyruvate dehydrogenase during aerobic metabolism (glycolysis), facilitating the conversion of

pyruvate to acetyl-CoA within the mitochondria. If a thiamine deficiency exists, pyruvate is unable to enter the citric acid cycle, instead being converted to lactate, which may lead to lactic acidosis.^{3,4}

Thiamine deficiency is largely a clinical diagnosis and if left untreated, may result in irreversible neurologic damage. Therefore, waiting for lab confirmation to confirm a deficiency is not advised. Moreover, plasma and serum thiamine levels have a low sensitivity and specificity, and are decreased in critically ill trauma patients and those requiring continuous renal replacement therapy.^{3,5} Whole blood assays may be a better reflection of total body stores, but are impractical in an acute care setting due to cost or long turnaround time which can take up to 2 weeks. Additionally, there is not a specific blood level that correlates with the appearance of signs and symptoms

(continued on page 26)

Kelly O'Donnell MS, RD, CNSD, Nutrition Support Specialist, University of Virginia Health System, Charlottesville, VA

(continued from page 24)

of deficiency. Identifying patients with risk factors such as alcoholism, persistent emesis, and malnutrition is the key to detecting thiamine deficiency.^{3,5-7} (see Table 1).

There are two major clinical manifestations of thiamine deficiency: Dry beriberi, which includes peripheral neuropathy and gait ataxia; more advanced symptoms include Wernicke's encephalopathy with its classic triad of ataxia, confusion and ocular changes.^{3,5,8} Wet beriberi includes high output heart failure, cardiac hypertrophy (especially of the right ventricle), lactic acidosis, and edema in lower extremities.^{3,5,8,9} (See Table 2).

Case

A 35-year-old female with a history of bipolar disorder and prior self-inflicted abdominal injury, resulting in exploratory surgery and bowel resection, recently presented to surgery clinic for evaluation of her ongoing abdominal pain, daily vomiting and reflux symptoms. She was referred to gastroenterology and underwent esophagogastroduodenoscopy and manometry, which showed:

- LA Grade C reflux esophagitis
- Hiatal hernia
- Erythematous duodenopathy
- Lower esophageal sphincter hypotension

The hiatal hernia was felt to be contributing to her gastroesophageal reflux disease and esophagitis, as well as cholelithiasis precipitating her biliary colic. She was subsequently admitted to the hospital and underwent an elective laparoscopic Nissen fundoplication, hiatal hernia repair and cholecystectomy. In the operating room, she was noted to have significant steatosis with hepatomegaly. Despite this, her operation was completed successfully and she was transferred to the regular surgical floor post-operatively. When questioned about the appearance of her liver, the patient acknowledged a "few drinks" per week. A nutrition evaluation revealed that the patient had suffered a severe weight loss of 26 pounds (180 down to 154 lbs. or a 15% loss over the previous 3 months) from frequent vomiting and an inability to eat. This prompted the initiation of 100 mg of intravenous (IV) thiamine per day starting on post-operative day (POD) 1; a clear liquid diet was begun and intravenous normal saline continued. Liver function tests peaked on POD 2 with alkaline phosphatase rising to 22 U/L (40-150 U/L), ALT 62 U/L (<55 U/L) and

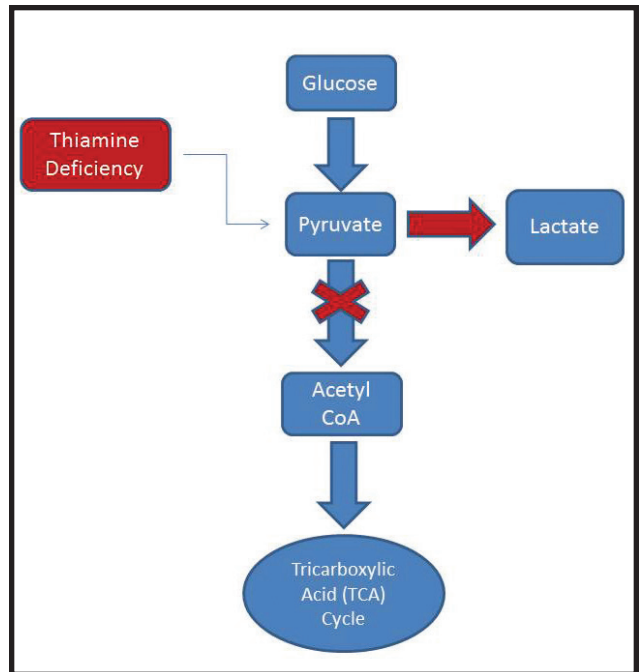


Figure 1. Thiamine deficiency impairs the entry of pyruvate into the TCA cycle which may lead to lactic acidosis.

AST 329 U/L (<35 U/L). During this time, lactic acid ranged from 1.0 to 1.3 mmol/L (0.5-2.2 mmol/L).

On POD4, she experienced confusion and dyspnea with a chest x-ray demonstrating bilateral pulmonary infiltrates suggestive of acute respiratory distress syndrome. She was transferred to the intensive care unit (ICU) and intubated. Her course was further complicated by severe lactic acidosis requiring a bicarbonate drip, sepsis requiring high dose vasopressors, and renal failure requiring continuous renal replacement therapy (CRRT). Low calorie parenteral nutrition with an additional 200 mg thiamine to avoid refeeding syndrome was initiated upon transfer to the ICU. She also continued to receive 100 mg IV thiamine. Although broad spectrum antibiotics were started, all percutaneous and central line blood cultures continued to be negative. A transthoracic echocardiogram showed a mildly dilated right ventricle.

On POD6, given persistent lactic acidosis and unable to identify a source of her sepsis, the patient returned to the operating room where she underwent a diagnostic laparoscopy converted to exploratory laparotomy with findings of 20-30 cm of dusky, dilated jejunum, but no evidence of spillage, injury, or septic source within the abdomen.

At this time, the patient's family was again

questioned about her alcohol use and it was revealed that the patient engaged in heavy drinking of 5-6 drinks per day up until the time of hospital admission. Based on this new information, as well as the preoperative excessive weight loss with persistent vomiting, a mildly dilated right ventricle, in addition to her lactic acidosis of unclear etiology, it was presumed the patient was thiamine deficient and thiamine was repleted aggressively with 500 mg IV three times per day over the next 3 days, followed by 250 mg IV thiamine daily for four more days.

Results

Supplementation with high dose IV thiamine was associated with a rapid reversal of lactic acidosis and a greater than 50% decrease in lactic acid levels within 8 hours (14.0 to 6.1 mmol/L) (see Table 4). Normalization of lactic acid levels occurred within 18 hours (POD7). Three days later, on POD10, she was weaned off pressor support and continuous renal replacement therapy was discontinued. She was extubated on POD 14. The patient subsequently underwent fascial closure, placement of retention sutures and was eventually discharged to a rehabilitation facility. Although liver failure and shock liver were considered as potential causes of her lactic acidosis, they typically take many days to weeks to correct.

DISCUSSION

Elevated lactate levels are often used as a prognostic tool in critical illness. There are many causes of lactic acidosis including sepsis, systemic hypoperfusion, medications and thiamine deficiency. Thiamine is essential for producing energy from glucose in the glycolytic pathway, but if a deficiency exists, pyruvate is instead converted to lactate (see Figure 1).

Table 2. Manifestations of Thiamine Deficiency

Dry beriberi	Wet beriberi
<ul style="list-style-type: none"> Peripheral neuropathy Muscle weakness Gait ataxia Parasthesias Wernicke’s Encephalopathy 	<ul style="list-style-type: none"> High output heart failure Heart hypertrophy especially of the right ventricle Tachycardia or bradycardia Dyspnea/ respiratory distress Edema in lower extremities; oliguria Lactic acidosis

Table 1. Risk Factors for Thiamine Deficiency^{3,5}

- ◆ Alcoholism
- ◆ Persistent vomiting
 - Bariatric surgery with persistent vomiting
 - Hyperemesis gravidarum
 - Chronic vomiting / gastroparesis
- ◆ Anorexia nervosa
- ◆ Hunger strikers
- ◆ Starvation/malnutrition or patients deprived of nutrients for a prolonged period of time for any reason
- ◆ Parenteral nutrition without added vitamins
- ◆ Unexplained lactic acidosis

There is large variability in thiamine prescribing practices, most revolving around the treatment of alcoholics. Only one randomized, double blind study using different doses of parenteral thiamine exists to date.¹⁰ A therapeutic effect was seen with the 200 mg dose of intramuscular thiamine in alcoholic patients taking a memory test. However, the sample size was small, there was a high rate of non-completion and thiamine administration was of short duration (2 days).

Thiamine is both inexpensive and safe. Because

Table 3. Guidelines for Thiamine Supplementation

<p>United Kingdom: 500 mg IV thiamine TID followed by 250 mg IV or IM for five days</p>
<p>European: 200 mg IV TID until symptoms resolve</p>
<p>American: 50-100 mg IV daily for a period of at least three days</p>

of the potentially devastating effects of undertreating thiamine deficiency, recommendations of higher doses have appeared in the literature.¹¹ In the United Kingdom, 500 mg IV thiamine 3 times daily is prescribed followed by 250 mg IV or IM for 5 days.¹² The European Guidelines suggest 200 mg IV three times daily until symptoms resolve.¹³ American guidelines suggest the lowest amounts of thiamine, ranging from 50-100 mg IV daily for a period of at least 3 days.¹¹ (see Table 3).

Thiamine deficiency as a cause of lactic acidosis in the critical care setting may be undiagnosed or misdiagnosed as a symptom of sepsis or hypoperfusion. In a prospective, observational study, Donnino and colleagues found that 10% of septic ICU patients (n = 30) had thiamine deficiency on admission, and an additional 10% developed a deficiency within 72 hours, yet only one of the 6 deficient patients received thiamine during their hospitalization. According to the authors, this was due to a lack of clinical recognition. Overall, there was no correlation with thiamine and lactate levels, however, when patients with acute liver injury were excluded, there was a significant negative correlation between thiamine and lactic acidosis.⁴

Two recent reports involving lactic acidosis due to thiamine deficiency were attributed to parenteral nutrition with limited or no multivitamins.^{14,15} All patients were admitted to the ICU and treated with 100 mg IV thiamine and within hours experienced a rapid decrease in lactate levels and ultimately a full recovery. In another case report, a 56-year-old alcohol misuser with recent weight loss and mild malnutrition was admitted to the ICU with lactic acidosis.¹⁶ He was treated with 300 mg IV thiamine and lactate levels normalized rapidly. This patient, however, experienced persistent cognitive deficits.

Of note, thiamine may be lost in critically ill

patients receiving continuous renal replacement therapy (CRRT). In a prospective randomized crossover trial by Berger, et al., 11 intensive care patients on CRRT had trace element and thiamine levels analyzed during CCRT. Trace elements including copper, selenium, and zinc, as well as thiamine, were found in the effluent of each patient. Hence, patients on CRRT may need higher doses of thiamine, especially if they are malnourished or alcohol misusers prior to the initiation of CRRT.¹⁷

CONCLUSION

Elevated lactate levels are often found in critically ill patients, most often due to hypoperfusion. Thiamine deficiency as a cause of lactic acidosis in the critical care setting may be underdiagnosed. This particular case study patient was admitted to the hospital with 3 major risk factors for thiamine deficiency including alcoholism, persistent vomiting, and severe malnutrition. Upon transfer to the ICU, she exhibited symptoms of wet beriberi including dyspnea, respiratory distress, oliguria, mild right ventricular hypertrophy and lactic acidosis. No source of sepsis was ever identified. It is unknown whether thiamine supplementation is solely responsible for the decrease in lactate levels; however the rapid drop after intravenous administration is consistent with other case studies in the literature. At the very least, it was thought to have been an important component of her clinical response. In retrospect, it would have been ideal to have obtained a baseline plasma thiamine level to compare to the patient's risk factors, signs and symptoms, the caveat being that waiting for blood draw results did not delay empiric treatment. Curiously, 100 mg of thiamine did not appear adequate to prevent lactic acidosis and only with the delivery of higher doses did this malnourished alcohol

(continued on page 30)

(continued from page 28)

Table 4. Patient's Hospital Course and Thiamine Dosing

POD	Lactic Acid (0.5-2.2 mmol/L)	AST/ALT (<35 U/L; <55 U/L)	Nutrient Source	IV Thiamine Given	CRRT	Pressors
1	n/a	n/a	Clear liquids started	n/a	n/a	n/a
2	1.3	387/65	Clear liquids	100 mg	n/a	n/a
4 ICU Transfer	1.0	122/39	TPN Started NPO	100 mg	n/a	Levophed
5	2.7 10 hours later: 11.9 8 hours later: 12.2	67/29	TPN held Dextrose 10% @ 50 mL/hr	200 mg 200 mg	started	Levophed, Dobutamine, vasopressin, phenylephrine
6	14.0 8 hours later: 6.1 9 hours later: 3.3	105/24	TPN held Dextrose 10% @ 50 mL/hr	600 mg 500 mg	continued	Same as above
7	1.7	110/24	TPN restarted	1100 mg	continued	Levophed, Dobutamine, vasopressin
10	2.0	87/26	TPN continued	250 mg	stopped	n/a

misuser respond. In addition, it may be that the CRRT pulled off a portion of the thiamine she received. Current guidelines for thiamine deficiency are not specific for the treatment of severe, life-threatening complications and more evidence is needed to clarify the appropriate dosage. Although most critical care practitioners would assume this case was a result of either septic shock lactic acidosis (~ 25% of septic shock cases a source for

infection is not found, nor do cultures grow anything), lactic acidosis from bowel ischemia (with the dusky bowel), lactic acidosis from poorly functioning liver and kidneys, or a combination of all three. However, in unexplained cases of lactic acidosis in a patient not responding as expected, consider thiamine deficiency. It is inexpensive and easy to treat. ■

(continued on page 32)

(continued from page 30)

References

1. Sehault J, Fitzpatrick J, Boran J. Lactic acidosis: an update. Clin Chem Lab Med. 2016 August 15 {Epub ahead of print}.
2. Iannelli A, Addeo P, Novellas S, et al. Wernicke’s encephalopathy after laparoscopic Roux-en-Y gastric bypass: a misdiagnosed complication. Obes Surg. 2010;20(11):1594-6.
3. Frank LL. Thiamin in Clinical Practice. JPEN Journal of Parenteral and Enteral Nutrition. 2015;39(5):503-20.
4. Donnino MW, Carney E, Cocchi MN, et al. Thiamine deficiency in critically ill patients with sepsis. J Crit Care. 2010;25(4):576-81.
5. Manzanares W, Hardy G. Thiamine supplementation in the critically ill. Curr Opin Clin Nutr Metab Care. 2011;14(6):610-7.
6. Walker J, Kepner A. Wernicke’s encephalopathy presenting as acute psychosis after gastric bypass. J Emerg Med. 2012;43(5):811-4.
7. Stroh C, Meyer F, Manger T. Beriberi, a severe complication after metabolic surgery - review of the literature. Obes Facts. 2014;7(4):246-52.
8. Dabar G, Harmouche C, Habr B, et al. Shoshin Beriberi in Critically-Ill patients: case series. Nutr J. 2015;14:51.
9. Klein M, Weksler N, Gurman GM. Fatal metabolic acidosis caused by thiamine deficiency. J Emerg Med. 2004;26(3):301-3.
10. Ambrose ML, Bowden SC, Whelan G. Thiamine treatment and working memory function of alcohol-dependent people: preliminary findings. Alcohol Clin Exp Res.2001;25(1):112-6.
11. Isenberg-Grzeda E, Chabon B, Nicolson SE. Prescribing thiamine to inpatients with alcohol use disorders: how well are we doing? J Addict Med. 2014;8(1):1-5.
12. Thomson AD, Cook CC, Touquet R, et al. The Royal College of Physicians report on alcohol: guidelines for managing Wernicke’s encephalopathy in the accident and Emergency Department. Alcohol Alcohol.2002;37(6):513-21.
13. Galvin R, Brathen G, Ivashynka A, et al. EFNS guidelines for diagnosis, therapy and prevention of Wernicke encephalopathy. Eur J Neurol. 2010;17(12):1408-18.
14. Da Silva YS, Horvat CM, Dezfulian C. Thiamin Deficiency as a Cause of Persistent Hyperlactatemia in a Parenteral Nutrition-Dependent Patient. JPEN Journal of Parenteral and Enteral Nutrition. 2015;39(5):604-6.
15. Giacalone M, Martinelli R, Abramo A, et al. Rapid reversal of severe lactic acidosis after thiamine administration in critically ill adults: a report of 3 cases. Nutr Clin Pract. 2015;30(1):104-10.
16. Amrein K, Ribitsch W, Otto R, et al. Severe lactic acidosis reversed by thiamine within 24 hours. Crit Care 2011;15(6):457.
17. Berger MM, Shenkin A, Revelly JP, et al. Copper, selenium, zinc, and thiamine balances during continuous venovenous hemodiafiltration in critically ill patients. Am J Clin Nutr. 2004;80(2):410-6.

PRACTICAL GASTROENTEROLOGY

REPRINTS

Special rates are available for quantities of 100 or more.

For further details visit our website:

practicalgastro.com

Answers to this month’s crossword puzzle:

1	E	S	O	P	H	A	G	I	T	I	S		7	B	A	8	G	
	L		R		E	E	B		T		I						E	
9	I	B	D		10	M	R	N	A		11	C	O	H	O	R	T	
	M		E		O	E				12	B		M		L			
13	I	R	R	U	P	T	S			14	L	E	A	K	O	U	15	T
	N				A					O		L		G			A	
16	A	G	17	E	N	T		18	C	E	C	A		19	Z	I	N	C
	T		O		H	O		K		20	P		C				H	
21	I	F	S		22	Y	A	N	G		23	K	R	A	S		Y	
	O		I				G			24	W		O			25	C	C
26	N	O	N	27		28	M	E	T	A	P	L	A	29	S	I	A	
	D			30	R	31	E	S		S		A	T				R	
32	I	N	33	F	A	R	C	T		34	H	A	P	L	O	I	D	
	E		A		G		E			S		O					I	
35	T	E	S	T	O	I	D			36	W	H	E	A	L		A	