

Attenuated Familial Adenomatous Polyposis: A Novel Treatment with Celecoxib

by Zachary S. Neubert, Mark Potter

INTRODUCTION

Attenuated familial adenomatous polyposis is characterized by multiple adenomatous polyps that develop later in life and prompt close screening due to a high propensity of malignant transformation. The usual curative treatment is surgical resection.³ This case describes the use of alternative medical therapy with COX-II inhibitors with near complete resolution of polyps.

Case Report

A 53-year-old African American male underwent a screening colonoscopy which revealed numerous polyps ranging in size from diminutive to large (Figure 1). His past medical history was significant for hypertension, insulin dependent diabetes, and hyperlipidemia. He had no known family history of colon cancer. Polyps were removed and found to be tubular adenomas.

Repeat colonoscopy 6 months later demonstrated more than 50 polyps with a right sided distribution; roughly 20 were removed and all again were found to be tubular adenomas. The patient was then sent for genetic testing which revealed attenuated familial adenomatous polyposis. Patient was referred to surgery, opted for a right hemicolectomy with continued surveillance instead of a subtotal colectomy. After a successful right hemicolectomy, surveillance colonoscopy revealed multiple more small to medium sized polyps (> 20) in the remaining colon.

Once again the patient decided to forgo a subtotal colectomy and opted instead to start chemoprevention, celecoxib 400mg twice daily with continued interval

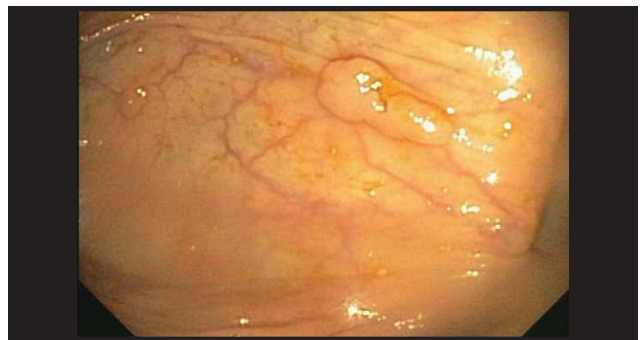

Figure 1.

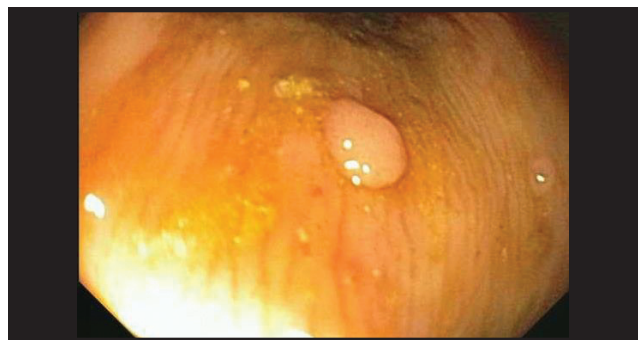

Figure 2.

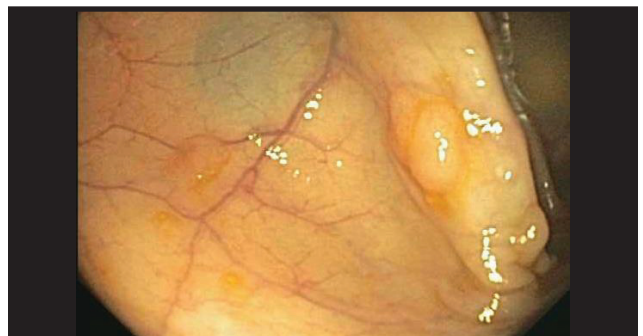

Figure 3.

Zachary S. Neubert, DO, Madigan Army Medical Center Internal Medicine Mark Potter, DO Associate Professor, Department of Gastroenterology, Department of Medicine, Madigan Army Medical Center, Tacoma, WA

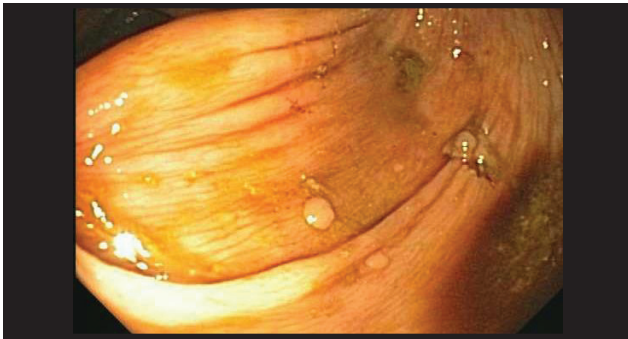


Figure 4.

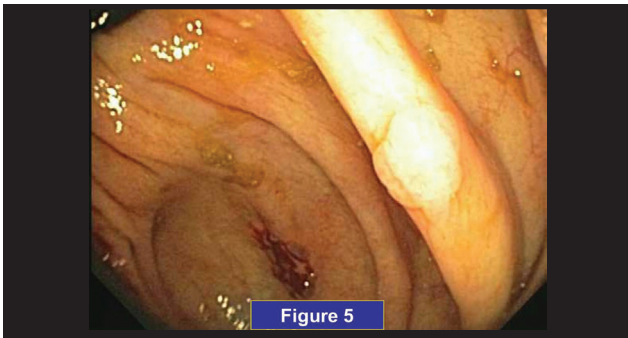


Figure 5.

surveillance. After 6 months of medical therapy surveillance colonoscopy showed that his polyp burden dramatically decreased. Only one small tubular adenoma was found.

Discussion

Attenuated FAP is a milder variation of FAP, characterized by an average age of 44 at presentation, oligopolyposis (less than 100 polyps), and with a right colonic distribution.^{2,3} There still exists nearly 100% incidence of colorectal cancer with these patients, averaging roughly 10-15 years past time of initial presentation and care must be taken to continue aggressive surveillance of disease burden. Attenuated FAP is characterized by MUTYH base-excision repair mutation without loss of the APC gene. There is a higher incidence of extra-colonic adenomatous polyps in patients who had prophylactic colectomies, including gastric fundus polyps and periampullary carcinoma, of which the latter is the major cause of death in these patients.² Thus it is imperative to continue ongoing gastrointestinal surveillance in these patients.

In 2001, FDA approved the use of COX-II inhibitors for chemoprophylaxis in patients with

Familial Adenomatous Polyposis (FAP) due to several randomized clinical trials showing significant tumor reduction.⁵ Use of COX-II inhibitors for attenuated FAP has been described in the literature only as a single case report with nine year follow-up as potential chemo preventative strategy with ongoing surveillance in lieu of surgical resection.⁶ Clinical trials currently underway are targeted at inhibiting the EGFR receptor which may cause reduced proliferation of polyps. It is still unclear whether reduction of polyps early in the disease process offers protection against malignant transformation later in life. If celecoxib becomes efficacious for this disease, it could offer patients an alternative non-surgical therapy which may reduce morbidity associated with colonic resection but would necessitate ongoing GI surveillance. It may bring about more risks involved in patients with multiple comorbidities given the FDA black box warning of increased incidence of gastrointestinal bleeding with use of NSAIDs as well as the adverse cardiovascular effects of MI and stroke.

To our knowledge, this is only the second case showing polyp eradication with use of celecoxib in patients with aFAP. This treatment for aFAP may be a novel non-surgical approach to this disease, and should be further investigated. ■

Disclaimer: The views expressed are those of the authors and do not reflect the official policy of the Department of the Army, the Department of Defense or the United States Government.

References

1. Colussi D, Brandi G, et al. Molecular Pathways involved in Colorectal Cancer: Implications for Disease Behavior and Prevention. *Int J Mol Sci.* 2013;14:8.
2. Ellis C. Inherited Colorectal Cancer Syndromes. *Clin Colon Rectal Surg.* 2005;18:3.
3. Ellis C. Colonic Adenomatous Polyposis Syndromes: Clinical Management. *Clin Colon Rectal Surg.* 2008;21:4.
4. Half E, Dani B, et al. Familial adenomatous polyposis. *Orphanet Journal Rare Dis.* 2009;4:22.
5. Steinbach G, Lynch, et al. The effect of celecoxib, a cyclooxygenase-2 inhibitor, in familial adenomatous polyposis. *N Engl J Med.* 2000; 342:1946-1952.
6. Ferguson C, Porter K et al. Nine year follow-up of a patient with attenuated familial adenomatous polyposis treated with cyclooxygenase-2 inhibitors. *Scandinavian journal of gastroenterology.* 2008;43(12):1534-1536.