

# Nocardiosis in a Patient with Crohn's Disease

by Julie Nguyen, Swathi Paleti, John A. Bonino

## INTRODUCTION

**N**ocardia is an intracellular pathogen with the potential to cause life-threatening disease, particularly in immunocompromised patients. Based on long-term data (nine years, 2000 patients), the incidence of *Nocardia* infection has been estimated at 0.01% in patients taking adalimumab.<sup>1</sup>

The diagnosis of *Nocardia* is often limited by clinical suspicion and local expertise of the diagnostic laboratory.<sup>2</sup>

## Case Description

A 36 year old male with a history of Crohn's disease, on chronic adalimumab therapy, presented to the emergency department after he sustained a forehead laceration while working in his backyard. The wound was cleansed in standard fashion and sutures placed. Later, during suture removal, he was noted to have a small single draining pustule. He was then prescribed a seven day course of oral trimethoprim-sulfamethoxazole.

Over the course of several days, he developed

---

Julie Nguyen, MD, Resident Physician, Internal Medicine, University of Kansas Medical Center  
Swathi Paleti, MBBS, Resident Physician, Internal Medicine, University of Kansas Medical Center  
John A. Bonino, MD, Assistant Professor, Internal Medicine, Gastroenterology, University of Kansas Medical Center

tender lymphadenopathy and fever prompting cessation of adalimumab and subsequent hospitalization. Wound cultures were obtained and subsequently grew *Nocardia arthritidis*.

Due to the development of a persistent cough, a computed tomography (CT) of his chest demonstrated multiple pulmonary nodules, some with cavitation. He was subsequently treated with a combination of intravenous (IV) trimethoprim-sulfamethoxazole and meropenem with improvement of his pustules and near complete resolution of the pulmonary nodules on subsequent imaging.

## Discussion

Tumor necrosis factor (TNF) is a cytokine produced by activated monocytes, macrophages and T lymphocytes involved in cell-mediated immunity. TNF interacts with other cytokines, including interferon-delta, to generate an immune response to intracellular pathogens such as *Mycobacterium tuberculosis*, *Listeria*, *Histoplasma* and *Nocardia*. Disruption of this pathway by anti-TNF medications, such as adalimumab, may increase rates of infection by such organisms.<sup>3</sup>

*Nocardia* are soil-borne, gram-positive, facultative intracellular bacteria. They are ubiquitous and found worldwide in dust, sand, soil and bodies of water. Respiratory transmission is presumed to be via contact with dust particles contaminated by the organism.<sup>4</sup>

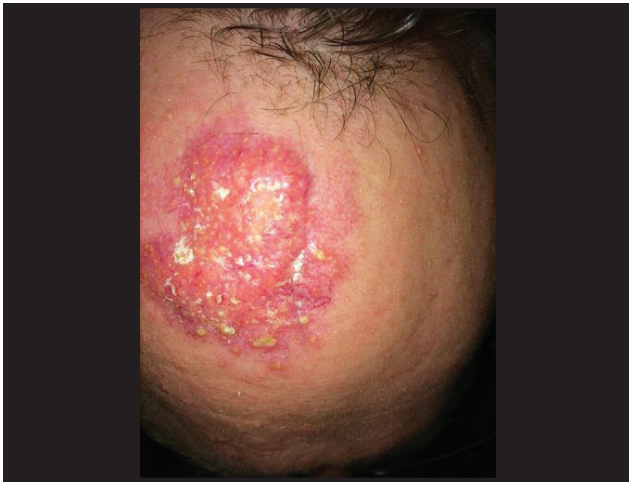

Figure 1. Before Antibiotics

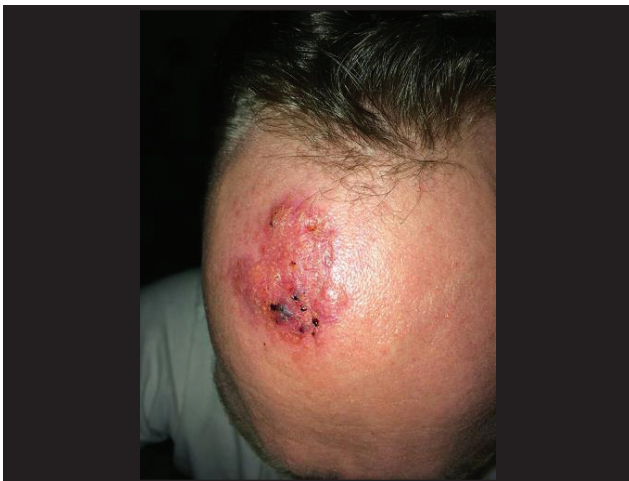

Figure 2. After Antibiotics

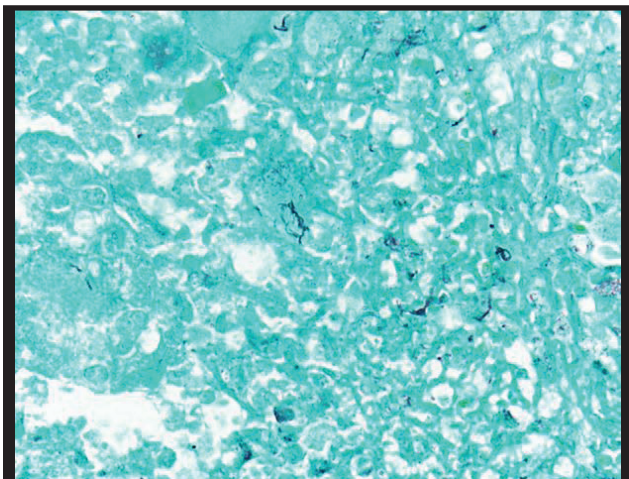


Figure 3.

*Nocardia* has a predilection for the lungs due to its ability to aerosolize, but infection may also occur via the skin or central nervous system.<sup>5,6</sup>

Cutaneous infections typically occur through open wounds contaminated with soil. Lesions may manifest as localized abscesses and mimic infection from pyogenic bacteria. Infection may also spread to regional lymph nodes and mimic sporotrichosis.<sup>2</sup>

The laboratory diagnosis of *Nocardia* requires a high level of suspicion, since these organisms are slow-growing and may lead to premature disposal of cultures. Histologically, *Nocardia* are strictly aerobic bacteria with branching filamentous structures. Standard blood cultures are rarely found to be positive. Confirmation and speciation require specialized polymerase chain reaction (PCR) testing.<sup>4</sup>

Initial antibiotic therapy includes IV trimethoprim-sulfamethoxazole for a minimum of three weeks. After three weeks, patients without immune dysfunction may be switched to oral trimethoprim-sulfamethoxazole until infection resolution. For those who are immunocompromised, duration of treatment may be extended beyond six months.<sup>7</sup>

The prognosis is poor (mortality rate >50%) for immunocompromised patients with disseminated nocardiosis, even those treated with appropriate antibiotics.<sup>5,8</sup>

## CONCLUSION

Cutaneous Nocardiosis should be considered in inflammatory bowel disease patients on anti-TNF therapy presenting with atypical or difficult to treat cutaneous infections to ensure timely diagnosis and treatment. ■

## References

1. Data on file, Rheumatoid Arthritis Integrated Summary of Safety, AbbVie.
2. Abreu C. Nocardia infections among immunomodulated inflammatory bowel disease patients: A review. *World Journal of Gastroenterology*. 2015;21(21):6491.
3. Johnston B, Conly J. Tumour necrosis factor inhibitors and infection: What is there to know for infectious diseases physicians?. *Can J Infect Dis Med Microbiol*. 2006;17(4):209-12.
4. Lerner PI. Nocardiosis. *Clin Infect Dis*. 1996;22:891-903.
5. Bush L. Nocardiosis. *Merck Manual*. 2015.
6. Nocardiosis. *Center for Disease Control*. 2013.
7. Chaussade H, Lebeaux D, Gras G, et al. Nocardia Arthritis: 3 Cases and Literature Review. *Medicine (Baltimore)*. 2015;94(42):e1671.
8. Martínez Tomás R, Menéndez Villanueva R, Reyes Calzada S, et al. Pulmonary nocardiosis: risk factors and outcomes. *Respirology*. 2007;12(3):394-400.